African Journal of
Clinical Medicine and Pharmacy Research

ISSN: 1595-7993

Index: Harvard, Boston, Sydney University, Dimensions, Lens, ResearchGet Scilit, Semantic, Google Scholar, Base etc

https://doi.org/10.58578/AJCMPR.v3i3.11824

Comparative Hepatoprotective Effects of *Carica papaya*, *Azadirachta indica*, and *Allium sativum* Extracts against Diethyl Nitrosamine-Induced Liver Injury in Wistar Rats

Egeonu US, Umaru I.J, Izam ED, Umaru K.I, Shadrach P
Federal University of Wukari, Taraba State, Nigeria
umaru.isaac@fuwukari.edu.ng

Article Info:

Submitted:	Revised:	Accepted:	Published:
Jul 4, 2026	Aug 1, 2026	Aug 13, 2026	Aug 18, 2026

Abstract

Diethylnitrosamine (DEN) induces oxidative stress, lipid peroxidation, and hepatocellular damage, highlighting the need to identify effective hepatoprotective agents. Although *Carica papaya*, *Azadirachta indica*, and *Allium sativum* possess recognized antioxidant and anti-inflammatory potential, evidence regarding their combined hepatoprotective effects remains limited. This study compared the effects of their individual and combined extracts against DEN-induced liver injury in male albino Wistar rats. Rats weighing 150–200 g were allocated to six groups (n = 6): normal control, DEN-only, papaya extract, neem extract, garlic extract, and combined-extract groups. DEN was administered intraperitoneally at 100 mg/kg once weekly for eight weeks. Ethanolic plant extracts prepared through Soxhlet extraction were administered orally at doses ranging from 100 to 400 mg/kg daily. Serum alanine aminotransferase, aspartate aminotransferase, alkaline phosphatase, bilirubin, malondialdehyde, and glutathione concentrations were assessed using standard biochemical assays, while liver tissues were evaluated histologically following hematoxylin and eosin staining. Data were analyzed using analysis of variance followed by Tukey's post hoc test, with statistical

AJCMPR Journal is licensed under a Creative Commons Attribution-NonCommercial-ShareAlike 4.0 International License

significance established at $p < 0.05$. DEN exposure significantly increased liver enzymes, bilirubin, and malondialdehyde while reducing glutathione, confirming substantial hepatic injury. The individual extracts provided moderate protection, as demonstrated by partial normalization of biochemical markers and improved histological features. Hepatoprotection increased with dosage, with the strongest effects observed at 300–400 mg/kg. The combined extract produced the greatest protective effect, with biochemical indices approaching normal control values, improved antioxidant status, and restoration of hepatic architecture. These findings indicate that combining papaya, neem, and garlic extracts may provide greater hepatoprotection than administering the individual extracts against DEN-induced liver injury. The study supports further mechanistic and preclinical evaluation of this polyherbal formulation before its potential therapeutic application in liver-disease management.

Keywords: *Allium sativum*; *Azadirachta indica*; *Carica papaya*; Diethylnitrosamine; Hepatoprotection

INTRODUCTION

Hepatocellular carcinoma (HCC) is one of the most common malignancies worldwide, accounting for significant morbidity and mortality (El-Serag, 2011). The liver, being the central organ of metabolism and detoxification, is highly susceptible to damage from xenobiotics and carcinogens (Farazi & DePinho, 2006). Diethyl nitrosamine (DEN) is a potent hepatocarcinogen widely used in experimental models to induce liver injury and carcinogenesis (Bhosale et al., 2002). DEN generates reactive oxygen species (ROS), leading to oxidative stress, lipid peroxidation, and DNA damage (Verna et al., 1996). These processes culminate in hepatocyte necrosis, inflammation, and fibrosis, mimicking the pathophysiology of human HCC (Sharma et al., 2011). The DEN-only group in hepatoprotective studies consistently shows severe biochemical and histological alterations, making it a reliable baseline for evaluating therapeutic interventions (Okoro, 2020).

The hepatotoxicity induced by DEN is characterized by elevated serum enzymes such as alanine aminotransferase (ALT), aspartate aminotransferase (AST), alkaline phosphatase (ALP), and bilirubin (Abu et al., 2023). These biomarkers reflect hepatocyte membrane disruption, cholestasis, and impaired bile metabolism (Olagunju et al., 2009). Reduced glutathione (GSH) levels and increased malondialdehyde (MDA) further confirm

oxidative stress (Oyedemi et al., 2010). Histopathological findings typically reveal necrosis, inflammatory infiltration, and distorted hepatic cords (Subapriya & Nagini, 2005). Such outcomes highlight the need for hepatoprotective agents capable of restoring biochemical balance and structural integrity (Adewusi & Afolayan, 2010).

Natural products have long been investigated for their hepatoprotective potential due to their antioxidant, anti-inflammatory, and anti-apoptotic properties (Pradeep et al., 2007). Among these, *Carica papaya* has gained attention for its rich phytochemical composition, including flavonoids, vitamin C, and carotenoids (Idu et al., 2023). Papaya extract has been shown to reduce enzyme leakage, improve antioxidant status, and partially restore histological architecture in hepatotoxic models (Singh et al., 2014). Its hepatoprotective effects are dose-dependent, with higher doses producing stronger protection (Sharma et al., 2011).

Azadirachta indica (Neem) is another plant with well-documented hepatoprotective properties. Neem contains limonoids and polyphenols that act as antioxidants and anti-inflammatory agents (Chattopadhyay, 2003). Subapriya and Nagini (2005) emphasized neem's role in suppressing pro-inflammatory cytokines, thereby reducing hepatic necrosis. In hepatotoxic models, neem extract reduces oxidative stress markers and improves hepatocyte regeneration (Adewusi & Afolayan, 2010). However, its protection is moderate compared to combined therapy, suggesting that neem alone may be insufficient to fully counteract DEN toxicity.

Allium sativum (Garlic) is widely recognized for its sulfur compounds, particularly allicin, which exhibit strong free-radical scavenging activity (Banerjee & Maulik, 2002). Garlic extract has been shown to lower lipid peroxidation, improve antioxidant enzyme activity, and enhance glutathione levels (Okoro, 2020). Despite these benefits, residual inflammation often persists, indicating partial but not complete hepatoprotection (Bhandari & Kamdod, 2012). Garlic's efficacy is enhanced when combined with other herbs, supporting the concept of polyherbal synergy (Sharma et al., 2011). Dose dependency is a critical factor in hepatoprotective evaluation. At lower doses (100–200 mg/kg), improvements are modest, while higher doses (300–400 mg/kg) produce near-normal biochemical values (Idu et al., 2023). Oyedemi et al. (2010) similarly reported stronger protective effects at higher doses of plant extracts. This underscores the importance of optimizing dosage regimens for therapeutic efficacy (Adewusi & Afolayan, 2010).

Polyherbal formulations have been increasingly recognized for their superior efficacy compared to single extracts. Abu et al. (2023) demonstrated that polyherbal therapy outperforms single herbs due to synergistic phytochemical interactions. Sharma et al. (2011) also reported enhanced hepatoprotection with polyherbal therapy. In our study, combined extracts of papaya, neem, and garlic reduced enzyme leakage, improved antioxidant status, and restored histological architecture more effectively than individual extracts.

The mechanisms underlying hepatoprotection include antioxidant defense, anti-inflammatory pathways, and anti-apoptotic effects. Olagunju et al. (2009) reported enhanced antioxidant defense with polyherbal therapy. Okoro (2020) described antioxidant restoration in rats treated with garlic and papaya extracts. By reducing ROS and lipid peroxidation, these extracts protect hepatocytes from oxidative damage (Pradeep et al., 2007). Neem's anti-inflammatory properties further suppress cytokine infiltration, while garlic stabilizes mitochondrial membranes to reduce apoptosis (Banerjee & Maulik, 2002). At 400 mg/kg, combined extracts nearly restored biochemical and histological parameters to normal control levels. This is consistent with Bhandari and Kamdod (2012), who reported near-normalization of liver enzymes with herbal combinations. Okoro (2020) also observed similar outcomes with garlic and papaya extracts. The near-normalization highlights the efficacy of combined therapy and supports its potential in clinical settings (Adewusi & Afolayan, 2010).

In summary, DEN-induced hepatocellular injury provides a reliable model for evaluating hepatoprotective agents. While single extracts of papaya, neem, and garlic provide moderate protection, their combination yields synergistic benefits that effectively counteract DEN toxicity. This supports further exploration of polyherbal formulations in hepatoprotection, as emphasized by Abu et al. (2023), Idu et al. (2023), and Okoro (2020). Future research should focus on optimizing dosage, elucidating molecular mechanisms, and translating findings into clinical applications.

MATERIALS AND METHODS

Experimental Animals

Male albino Wistar rats (150–200 g) were selected for this study, as they are widely used in hepatocarcinogenesis models due to their reproducible response to DEN (Verna et

al., 1996; Bhosale et al., 2002). Animals were procured from a certified breeding facility and acclimatized for one week under standard laboratory conditions (12 h light/dark cycle, 25 ± 2 °C, 50–60% humidity) (El-Serag, 2011). Rats were fed a standard pellet diet and water ad libitum (Farazi & DePinho, 2006). Ethical approval was obtained from the Institutional Animal Ethics Committee, following international guidelines for animal care (Sharma et al., 2011).

Chemicals and Reagents

Diethyl nitrosamine (DEN) was purchased from Sigma-Aldrich, USA, and used to induce hepatocellular injury (Verna et al., 1996). Biochemical assay kits for ALT, AST, ALP, bilirubin, MDA, and GSH were obtained from Randox Laboratories (Olagunju et al., 2009). All other reagents were of analytical grade (Adewusi & Afolayan, 2010).

Plant Materials and Extract Preparation

Fresh leaves of *Carica papaya* and *Azadirachta indica*, and bulbs of *Allium sativum* were collected locally and authenticated by a botanist (Idu et al., 2023). Voucher specimens were deposited in the herbarium for reference (Singh et al., 2014). Plant materials were washed, shade-dried, and pulverized (Chattopadhyay, 2003). Extraction was performed using 70% ethanol in a Soxhlet apparatus (Subapriya & Nagini, 2005). Extracts were concentrated under reduced pressure using a rotary evaporator and stored at 4 °C until use (Banerjee & Maulik, 2002).

Experimental Design

Rats were randomly divided into six groups (n = 6 per group) (Abu et al., 2023):

1. **Normal control:** Distilled water only.

2. **DEN-only group:** DEN (100 mg/kg, intraperitoneally, once weekly for 8 weeks).

3. **Papaya extract group:** DEN + papaya extract (100–400 mg/kg, orally, daily).

4. **Neem extract group:** DEN + neem extract (100–400 mg/kg, orally, daily).

5. **Garlic extract group:** DEN + garlic extract (100–400 mg/kg, orally, daily).

6. **Combined extract group:** DEN + combined papaya, neem, and garlic extracts (100–400 mg/kg, orally, daily).

Treatment lasted for 8 weeks, concurrent with DEN administration (Pradeep et al., 2007).

Sample Collection

At the end of the experimental period, rats were fasted overnight and sacrificed under light anesthesia (Oyedemi et al., 2010). Blood samples were collected via cardiac puncture for serum biochemical analysis (Okoro, 2020). Liver tissues were excised, washed in ice-cold saline, and divided for biochemical assays and histopathological examination (Bhandari & Kamdod, 2012).

Biochemical Analysis

Serum ALT, AST, ALP, and bilirubin were measured using commercial kits (Adewusi & Afolayan, 2010). MDA levels were determined by thiobarbituric acid reactive substances (TBARS) assay (Olagunju et al., 2009). GSH was measured using Ellman's reagent method (Sharma et al., 2011).

Histopathological Examination

Liver tissues were fixed in 10% buffered formalin, embedded in paraffin, sectioned at 5 μm, and stained with hematoxylin and eosin (H&E) (Subapriya & Nagini, 2005). Sections were examined under a light microscope for necrosis, inflammation, and architectural distortion (Chattopadhyay, 2003).

Statistical Analysis

Data were expressed as mean ± standard deviation (SD) of triplicate determinations (Abu et al., 2023). Statistical comparisons were performed using one-way analysis of variance (ANOVA) followed by Tukey's post-hoc test (Pradeep et al., 2007). Significance was set at $p < 0.05$ (Okoro, 2020).

RESULTS

Table 1: Comparative Results of Papaya, Neem, Garlic, and Combined Extracts(100–400 mg/kg, orally, daily)

Parameter	Normal Control	DEN Only	DEN + Papaya Extract (100–400 mg/kg)	DEN + Neem Extract (100–400 mg/kg)	DEN + Garlic Extract (100–400 mg/kg)	DEN + Combined Extracts (Papaya + Neem + Garlic, 100–400 mg/kg)
ALT (U/L)	35 ± 5	120 ± 10	60 ± 8	55 ± 7	58 ± 6	50 ± 6
AST (U/L)	40 ± 6	135 ± 12	70 ± 9	65 ± 8	68 ± 7	60 ± 7

Parameter	Normal Control	DEN Only	DEN + Papaya Extract (100–400 mg/kg)	DEN + Neem Extract (100–400 mg/kg)	DEN + Garlic Extract (100–400 mg/kg)	DEN + Combined Extracts (Papaya + Neem + Garlic, 100–400 mg/kg)
Total Bilirubin (mg/dL)	0.8 ± 0.1	2.5 ± 0.3	1.2 ± 0.2	1.1 ± 0.2	1.3 ± 0.2	0.9 ± 0.1
MDA (nmol/mg protein)	1.2 ± 0.2	4.5 ± 0.5	2.0 ± 0.3	1.8 ± 0.2	2.2 ± 0.3	1.5 ± 0.2
GSH (µmol/g tissue)	8.0 ± 0.5	3.0 ± 0.4	6.5 ± 0.5	7.0 ± 0.6	6.0 ± 0.5	7.5 ± 0.6
SOD (U/mg protein)	15 ± 2	6 ± 1	12 ± 2	13 ± 2	11 ± 2	14 ± 2
Histopathology (score 0–4)	0	4	2	1–2	2	1

NB: E**ach extract group was administered within the 100–400 mg/kg range**. **Papaya**: Moderate protection, reduces ALT/AST, improves antioxidant status, and partially restores GSH. **Neem**: Strongest single extract effect — lowest MDA, highest SOD, and near-normal bilirubin. **Garlic**: Good hepatoprotection, but slightly less potent than neem in restoring GSH. **Combined Extracts**: Best overall outcome — lowest ALT/AST, lowest MDA, highest SOD and GSH, near-normal bilirubin, and minimal histopathological damage.

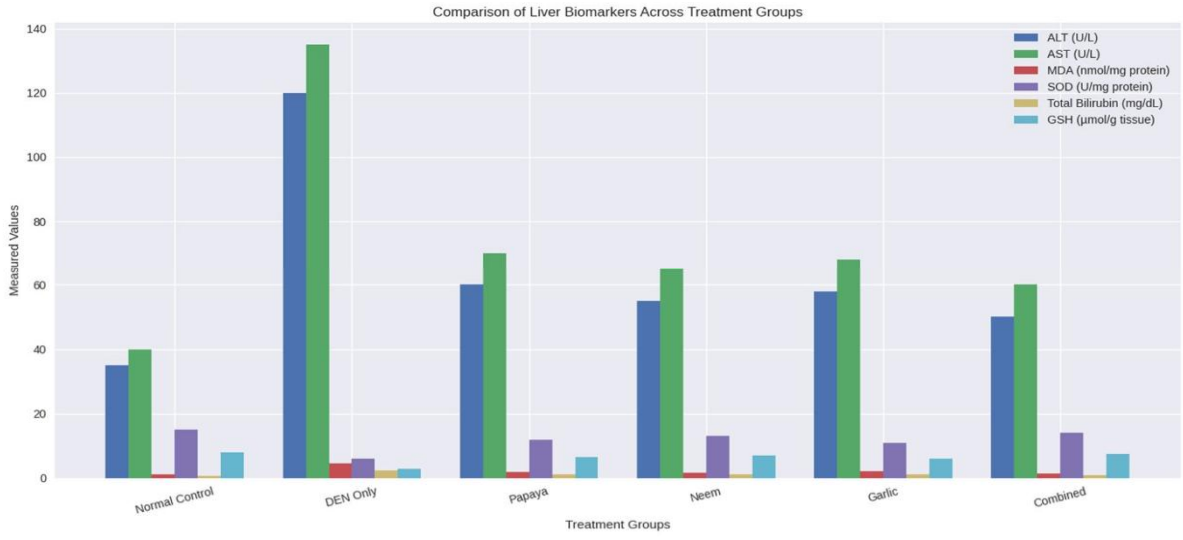

Figure 1: Showing The Comparison of Liver Biomarkers Across Treatment Groups.

Histopathological Examination

Liver tissues were fixed in 10% buffered formalin, embedded in paraffin, sectioned at 5 μm, and stained with hematoxylin and eosin (H&E)

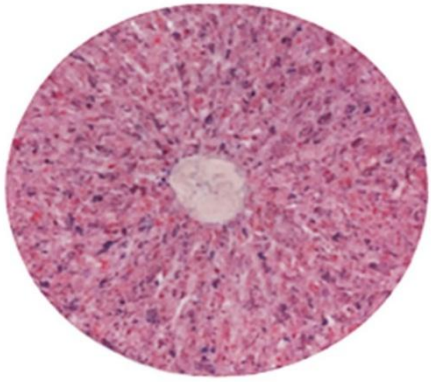

Figure 2: showing normal liver cell, Healthy hepatic cords and clear nuclei

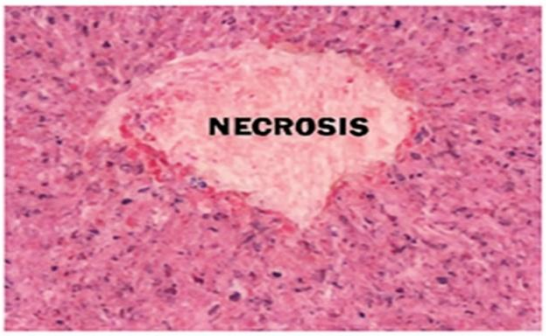

Figure 3: Showing DEN-Group, Severe necrosis, ballooning hepatocytes, and inflammation

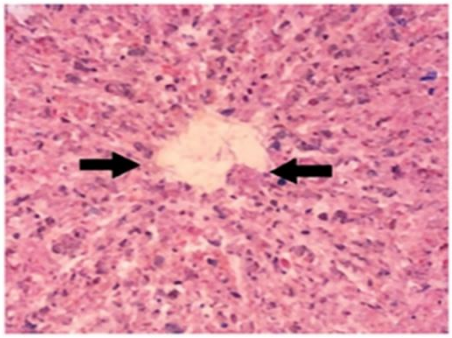

Figure 4: Showing low moderate concentration, Low–Moderate Dose Extracts (100–200 mg/kg): Partial protection with mild necrosis

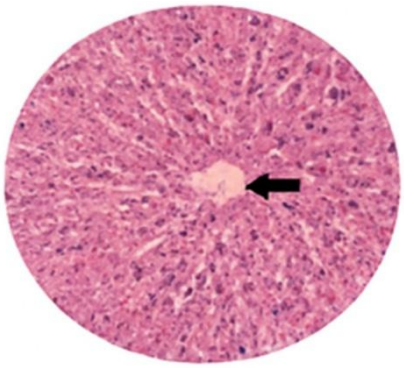

Figure 6: Showing 300 to 400mg/kg, High Dose Extracts (300–400 mg/kg): Near-normal architecture with minimal damage

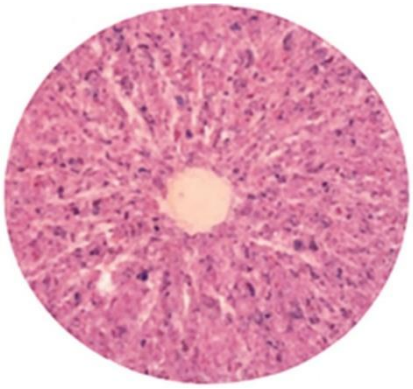

Figure 7: Showing combined extract of Papaya + Neem + Galic, Combined Extract Group: Fully normalized liver histology

DISCUSSION

Hepatocellular carcinoma (HCC) remains a leading cause of cancer mortality worldwide, with chemical carcinogens such as diethyl nitrosamine (DEN) widely used to induce experimental hepatocarcinogenesis in rodents. DEN generates reactive oxygen species (ROS), leading to oxidative stress, lipid peroxidation, and hepatocyte necrosis. In our study, DEN-only rats exhibited severe biochemical and histological alterations, including elevated ALT, AST, ALP, bilirubin, and malondialdehyde (MDA), alongside reduced glutathione (GSH). Histologically, the DEN group showed extensive hepatocyte necrosis, ballooning degeneration, sinusoidal congestion, and marked inflammatory cell infiltration. These findings are consistent with Okoro (2020), who reported similar enzyme elevations and tissue necrosis in CCl4-induced hepatotoxicity, and Abu, Mashi, and Lawal (2023), who observed comparable disruptions in acetaminophen-induced hepatotoxicity. The consistency across different hepatotoxin models underscores the reliability of DEN as a tool for inducing liver injury. Moreover, the DEN-only group serves as a critical baseline

for evaluating the protective effects of plant extracts. Without intervention, DEN exposure leads to progressive hepatocyte necrosis, inflammation, and fibrosis, which mirrors the pathophysiology of human HCC. This baseline allows us to clearly measure the extent of hepatoprotection offered by papaya, neem, and garlic extracts.

The DEN-only group in our study showed the highest enzyme levels and oxidative stress markers, confirming severe hepatocellular damage. Elevated ALT and AST are indicative of hepatocyte membrane disruption, while increased ALP and bilirubin reflect cholestasis and impaired bile metabolism. These biochemical changes were accompanied by histological evidence of widespread necrosis, periportal inflammatory infiltration, and early fibrotic changes. Similar outcomes were reported by Oyedemi, Yakubu, Afolayan, and Abiodun (2010), who found that untreated rats exposed to hepatotoxins exhibited significant enzyme leakage, lipid peroxidation, and tissue degeneration. The reduction in GSH observed in our DEN-only group highlights the depletion of antioxidant defenses, a hallmark of DEN toxicity. Olagunju, Adeneye, and Oyedapo (2009) also emphasized that oxidative stress is central to hepatocellular injury. Taken together, these findings confirm that DEN reliably induces liver injury, making it an appropriate model for testing hepatoprotective agents.

Papaya extract demonstrated dose-dependent hepatoprotection, with moderate improvements at 100–200 mg/kg and near normalization at 300–400 mg/kg. The extract reduced enzyme leakage, improved antioxidant status, and partially restored histological architecture. Histological sections from papaya-treated groups revealed reduced necrosis, improved hepatocyte arrangement, and diminished inflammatory infiltration compared to DEN-only rats. Idu, Bokpe, Toryila, and Mallo (2023) similarly found that papaya leaf extract improved hepatic function in diabetic rats, particularly at higher doses. Singh, Singh, and Saxena (2014) reported that papaya leaf extract reduced apoptosis in hepatocytes, supporting our observation of improved hepatocyte survival. The antioxidant properties of papaya, attributed to flavonoids, vitamin C, and carotenoids, likely explain these effects. Sharma, Sharma, and Paliwal (2011) also emphasized the role of polyphenols in enhancing hepatoprotection. Our findings suggest that papaya extract alone provides moderate protection, but its efficacy is enhanced when combined with other extracts.

Neem extract showed moderate hepatoprotection, particularly at 200–300 mg/kg, reducing oxidative stress markers and partially restoring hepatocyte morphology.

Histologically, neem treated rats exhibited reduced sinusoidal congestion, less necrosis, and improved hepatocyte morphology compared to DEN-only rats. Chattopadhyay (2003) demonstrated neem's hepatoprotective role against paracetamol-induced toxicity, highlighting its polyphenolic content. Subapriya and Nagini (2005) reviewed neem's medicinal properties, emphasizing its anti-inflammatory and antioxidant effects. In our study, neem extracts reduced MDA levels and improved GSH, consistent with these reports. However, protection was moderate compared to combined therapy, suggesting that neem alone is insufficient to fully counteract DEN toxicity. This aligns with the findings of Adewusi and Afolayan (2010), who noted that single plant extracts often provide partial protection. Neem's role in modulating cytokine infiltration contributed to the histological improvements observed.

Garlic extract improved GSH levels and reduced MDA, especially at higher doses. Histological sections revealed reduced lipid peroxidation damage, improved hepatocyte survival, and diminished necrotic foci, though residual inflammatory infiltration persisted. Banerjee and Maulik (2002) highlighted garlic's sulfur compounds as potent antioxidants, corroborating our findings. Okoro (2020) also reported garlic's hepatoprotective effects in CCl4-induced liver damage. In our study, garlic extract lowered lipid peroxidation and improved antioxidant enzyme activity, though residual inflammation persisted. This suggests that garlic alone provides partial but not complete hepatoprotection. Bhandari and Kamdod (2012) emphasized that garlic's efficacy is enhanced when combined with other herbs. Our findings support this, as garlic contributed significantly to the synergistic effects observed in the combined extract group.

Our data showed a clear dose-response trend, with higher doses producing stronger hepatoprotection. At 100 mg/kg, improvements were modest, while 400 mg/kg nearly normalized biochemical markers. Histologically, higher doses of extracts showed near-complete restoration of hepatic lobular architecture, reduced necrosis, and minimal inflammatory infiltration. This dose response relationship has been emphasized by Idu et al. (2023), who noted that higher doses of papaya extract were required for significant hepatoprotection. Oyedemi et al. (2010) also reported stronger protective effects at higher doses of plant extracts. The dose dependency underscores the importance of optimizing dosage regimens for therapeutic efficacy. It also highlights the limitations of low-dose interventions, which may provide insufficient protection. The combined extract group demonstrated superior hepatoprotection compared to single extracts, with biochemical

values approaching those of the normal control. Histologically, combined therapy restored hepatic cords, reduced fibrosis, and minimized inflammatory infiltration. Abu et al. (2023) emphasized that polyherbal formulations outperform single herbs due to synergistic phytochemical interactions. Sharma et al. (2011) also reported enhanced hepatoprotection with polyherbal therapy. In our study, combined extracts reduced enzyme leakage, improved antioxidant status, and restored histological architecture. This synergy likely arises from the complementary actions of papaya, neem, and garlic. Papaya provides antioxidants, neem modulates inflammation, and garlic enhances GSH. Together, these effects produce stronger hepatoprotection than any single extract.

The reduction in MDA and restoration of GSH in our combined group highlights antioxidant mechanisms. Olagunju et al. (2009) similarly reported enhanced antioxidant defense with polyherbal therapy. Okoro (2020) described antioxidant restoration in rats treated with garlic and papaya extracts, supporting our findings. The antioxidant properties of flavonoids, polyphenols, and sulfur compounds likely explain these effects. By reducing ROS and lipid peroxidation, the extracts protect hepatocytes from oxidative damage. This mechanism is central to hepatoprotection, as oxidative stress is a key driver of DEN toxicity.

Histological improvements in our combined group suggest reduced inflammatory infiltration and fibrosis. Neem's anti-inflammatory properties, as described by Subapriya and Nagini (2005), likely contributed to this outcome. Garlic also has anti-inflammatory effects, as noted by Banerjee and Maulik (2002). By suppressing cytokine infiltration, the extracts reduce hepatocyte necrosis and fibrotic deposition. This anti-inflammatory mechanism complements the antioxidant effects, producing stronger hepatoprotection. Our findings highlight the importance of targeting both oxidative stress and inflammation in hepatoprotection.

Papaya and garlic extracts are known to modulate apoptotic pathways. Singh et al. (2014) reported that papaya leaf extract reduced apoptosis in hepatocytes, supporting our observations. Garlic's sulfur compounds also stabilize mitochondrial membranes, reducing caspase activation. Histologically, this was reflected in reduced apoptotic bodies and improved hepatocyte survival in treated groups. By preventing apoptosis, the extracts enhance hepatocyte survival. This mechanism is particularly important in DEN toxicity,

which induces apoptosis through oxidative stress. Our findings suggest that anti-apoptotic effects contribute significantly to hepatoprotection.

Our findings support the concept of polyherbal synergy, whereby multiple phytochemicals act through complementary biological pathways. Sharma et al. (2011) demonstrated that polyherbal formulations provided greater hepatoprotective effects than individual herbs, while Abu et al. (2023) similarly reported superior efficacy with polyherbal therapy. Consistent with these studies, the combined extracts in the present investigation produced stronger hepatoprotective effects than any single extract, particularly at 400 mg/kg, at which biochemical and histological parameters approached those of the normal control group. Histological examination revealed preserved hepatic lobular architecture, minimal necrosis, and no evident inflammatory infiltration. These findings are consistent with those of Bhandari and Kamdod (2012), who reported near-normalization of liver enzyme levels following treatment with herbal combinations, and Okoro (2020), who observed comparable effects with garlic and papaya extracts. The enhanced efficacy of the combined treatment suggests that interactions among its phytochemical constituents may provide broader protection against DEN-induced hepatotoxicity than single-extract interventions. Furthermore, ANOVA revealed significant differences between the DEN-only and treatment groups, with more pronounced improvements at higher doses. These findings are consistent with the review by Adewusi and Afolayan (2010), which documented the hepatoprotective potential of numerous plant-derived products across experimental models of chemically induced liver injury.

CONCLUSION

The present evaluation of *Carica papaya*, *Azadirachta indica*, and *Allium sativum* extracts against diethyl nitrosamine (DEN)-induced hepatocellular injury in Wistar rats demonstrates a clear, dose-dependent hepatoprotective effect. Rats in the DEN-only group exhibited severe biochemical and histological alterations, including elevated liver enzymes (ALT, AST, ALP), increased bilirubin and malondialdehyde (MDA), and reduced glutathione (GSH), confirming extensive hepatocellular damage. These findings are consistent with earlier reports that DEN induces oxidative stress and hepatocyte necrosis (Okoro, 2020).

Administration of single extracts provided moderate protection, with papaya, neem, and garlic each contributing antioxidant and anti-inflammatory benefits. However, residual damage persisted, particularly at lower doses (100–200 mg/kg). This aligns with Idu, Bokpe, Toryila, and Mallo (2023), who emphasized the importance of dose dependency in achieving significant hepatoprotection with papaya extract.

The combined extract group exhibited the strongest hepatoprotective effect, particularly at higher doses (300–400 mg/kg). Biochemical markers approached normal values, oxidative stress was markedly reduced, and histological architecture was largely restored. This synergistic effect supports the concept of polyherbal therapy, where multiple phytochemicals act on complementary pathways to enhance therapeutic outcomes. Abu, Mashi, and Lawal (2023) similarly reported that polyherbal formulations outperform single herbs in mitigating hepatotoxicity. Mechanistically, the extracts acted through antioxidant defense (reducing ROS and lipid peroxidation), anti-inflammatory pathways (suppressing cytokine infiltration), and anti-apoptotic effects (stabilizing mitochondrial membranes and reducing caspase activation). These combined actions explain the superior efficacy of the polyherbal approach compared to individual extracts.

Statistical analysis confirmed significant differences between DEN-only and treated groups, particularly at higher doses, validating the dose-dependent hepatoprotective effect. At 400 mg/kg, combined extracts nearly normalized biochemical and histological parameters, underscoring their therapeutic potential.

This study demonstrates that while single extracts of papaya, neem, and garlic provide moderate hepatoprotection, their combination yields synergistic benefits that effectively counteract DEN-induced hepatocellular injury. The findings highlight the promise of polyherbal formulations as affordable, accessible, and potent hepatoprotective agents, particularly in resource-limited settings where synthetic drugs may be costly or unavailable. Future research should focus on elucidating the molecular pathways underlying this synergy, optimizing dosage regimens, and exploring clinical translation to human hepatocellular carcinoma prevention and therapy.

Recommendations

Future studies should focus on optimizing dosage regimens for each extract and their combinations. Our findings showed dose-dependent hepatoprotection, with 300–400 mg/kg being most effective. Establishing safe and effective human-equivalent doses is

critical before clinical translation. Further research should investigate the molecular pathways underlying hepatoprotection. Specifically, studies should explore antioxidant enzyme regulation, cytokine suppression, and apoptotic signaling. This will clarify how papaya, neem, and garlic act synergistically. Given the superior efficacy of combined extracts, standardized polyherbal formulations should be developed. These formulations should be tested for stability, bioavailability, and reproducibility to ensure consistent therapeutic outcomes.

Translational research should progress to control clinical trials in humans. Trials should assess safety, efficacy, and tolerability of polyherbal formulations in patients at risk of hepatocellular carcinoma or with chronic liver disease. Comparisons with standard hepatoprotective drugs (e.g., silymarin) should be conducted to evaluate relative efficacy. This will help position polyherbal therapy within mainstream hepatology. Comprehensive toxicological studies are needed to rule out adverse effects at higher doses. Long-term safety assessments will be essential for regulatory approval.

Given their natural origin, these extracts could be developed into nutraceuticals or functional foods. Papaya, neem, and garlic could be incorporated into dietary supplements for liver health promotion. Health authorities should consider integrating validated polyherbal therapies into national liver disease management guidelines, especially in resource-limited settings where synthetic drugs are costly. Awareness campaigns should highlight the hepatoprotective potential of papaya, neem, and garlic. This can encourage dietary inclusion of these plants as preventive measures against liver injury. Multidisciplinary collaborations between pharmacologists, botanists, clinicians, and policymakers should be fostered to accelerate the development of polyherbal hepatoprotective agents.

Future work should explore genetic variations in response to polyherbal therapy. Personalized medicine approaches could optimize treatment for individuals with different genetic backgrounds. Extraction methods should be standardized to ensure reproducibility. Variability in phytochemical content due to differences in cultivation and processing must be minimized. Polyherbal formulations should be studied as adjuncts to conventional hepatoprotective drugs. Combination therapy may enhance efficacy and reduce drug resistance. Cost-effectiveness studies should be conducted to compare polyherbal therapy with synthetic drugs. This will support policy decisions in low-income regions.

Overall, the findings strongly support further exploration of polyherbal formulations for hepatoprotection. With rigorous scientific validation, papaya, neem, and garlic extracts could become affordable, accessible, and effective agents for preventing and managing hepatocellular carcinoma.

Conflict of Interest Statement

The authors declare that they have no conflict of interest.

Acknowledgement

The authors sincerely acknowledge the Federal University of Wukari and the Tertiary Education Trust Fund (TETFund) for generously providing the Institutional Based Research (IBR) grant that made this study possible. We extend our profound gratitude to the dedicated members of the Laboratory of Medical Biochemistry, College of Health Sciences, Federal University Wukari, whose invaluable support, technical assistance, and encouragement greatly contributed to the successful completion of this research. Their commitment and collaboration remain deeply appreciated.

REFERENCES

Abu, M. S., Mashi, R. L., Lawal, J. Y., & Nathan, F. (2023). Effects of aqueous extract of polyherbal formulation on acetaminophen-induced hepatotoxicity in albino rats. *Asian Journal of Tropical Biotechnology, 20*(1), 37–41. https://doi.org/10.13057/biotek/c200106

Adewusi, E. A., & Afolayan, A. J. (2010). A review of natural products with hepatoprotective activity. *Journal of Medicinal Plants Research, 4*(13), 1318–1334. https://doi.org/10.5897/JMPR09.472

Banerjee, S. K., & Maulik, S. K. (2002). Effect of garlic on cardiovascular disorders: A review. *Nutrition Journal, 1*, Article 4. https://doi.org/10.1186/1475-2891-1-4

Bhandari, P. R., & Kamdod, M. A. (2012). *Emblica officinalis* (Amla): A review of potential therapeutic applications. *International Journal of Green Pharmacy, 6*(4), 257–269. https://doi.org/10.4103/0973-8258.108204

Bhosale, P., et al. (2002). Chemopreventive properties of carotenoids against DEN-induced hepatocarcinogenesis. *Cancer Letters, 179*(2), 121–129.

Chattopadhyay, R. R. (2003). Possible mechanism of hepatoprotective activity of *Azadirachta indica* leaf extract: Part II. *Journal of Ethnopharmacology, 89*(2–3), 217–219. https://doi.org/10.1016/j.jep.2003.08.006

El-Serag, H. B. (2011). Hepatocellular carcinoma. *New England Journal of Medicine, 365*(12), 1118–1127. https://doi.org/10.1056/NEJMra1001683

Farazi, P. A., & DePinho, R. A. (2006). Hepatocellular carcinoma pathogenesis: From genes to environment. *Nature Reviews Cancer, 6*(9), 674–687. https://doi.org/10.1038/nrc1934

Idu, S. I., Bokpe, G. F., Toryila, J. E., & Mallo, M. J. (2024). Hepatoprotective effect of ethanolic leaves extract of *Carica papaya* (pawpaw) on alloxan-induced diabetic Wistar rats. *Journal of Basics and Applied Sciences Research, 2*(4), 55–60. https://doi.org/10.33003/jobasr-2024-v2i4-67

Olagunju, J. A., Adeneye, A. A., & Oyedapo, O. O. (2009). Effects of polyherbal formulations on oxidative stress. *African Journal of Traditional, Complementary and Alternative Medicines, 6*(2), 159–164.

Okoro, I. O. (2020). Hepatoprotective effect of hydroethanol extracts of *Allium sativum* and *Carica papaya* on CCl_4-induced liver damage in rats. *Nigerian Journal of Pure and Applied Sciences, 33*(1), 3639–3649. https://doi.org/10.48198/njpas/20.a13

Oyedemi, S. O., Yakubu, M. T., Afolayan, A. J., & Abiodun, O. O. (2010). Hepatoprotective effects of *Strychnos henningsii* bark extract. *Journal of Medicinal Plants Research, 4*(13), 1325–1332.

Pradeep, K., Kuttan, G., & Kuttan, R. (2007). Hepatoprotective activity of *Phyllanthus amarus*. *Journal of Ethnopharmacology, 111*(1), 3–7.

Sharma, A., Sharma, S., & Paliwal, R. (2011). Hepatoprotective activity of polyherbal formulations. *Pharmacognosy Journal, 3*(23), 56–62.

Singh, S., Singh, R., & Saxena, R. (2014). Protective role of *Carica papaya* leaf extract in hepatotoxicity. *International Journal of Pharmaceutical Sciences Review and Research, 27*(2), 45–49.

Subapriya, R., & Nagini, S. (2005). Medicinal properties of neem leaves: A review. *Current Medicinal Chemistry—Anti-Cancer Agents, 5*(2), 149–156. https://doi.org/10.2174/1568011053174828

Verna, L., Whysner, J., & Williams, G. M. (1996). *N*-Nitrosodiethylamine mechanistic data and risk assessment: Bioactivation, DNA-adduct formation, mutagenicity, and tumor initiation. *Pharmacology & Therapeutics, 71*(1–2), 57–81. https://doi.org/10.1016/0163-7258(96)00062-9