African Journal of
Biochemistry and Molecular Biology Research

ISSN : 1595-7926

Index: Harvard, Boston, Sydney University, Dimensions, Lens, ResearchGet Scilit, Semantic, Google Scholar, Base etc

https://doi.org/10.58578/AJBMBR.v3i1.9306

Effects of Methanol Leaf and Root Extracts of *Lophira lanceolata* on Haematological Indices and Tissue Histology in *Bitis arietans* Venom-Induced Toxicity in Wistar Rats

Emmanuel Askeb-nde Joel, Isaac John Umaru, Kyugah Jacob Tersur, Sukyakma Manu
Federal University Wukari, Taraba State, Nigeria
askebpuri@gmail.com

Article Info:

Submitted:	Revised:	Accepted:	Published:
Jan 12, 2026	Feb 21, 2026	Mar 8, 2026	Mar 13, 2026

Abstract

Snakebite envenomation frequently causes severe haematological disturbances through venom-induced haemotoxicity and systemic inflammatory responses. This study investigated the restorative effects of methanol leaf and root extracts of *Lophira lanceolata* on haematological indices in *Bitis arietans* venom-intoxicated Wistar rats. Thirty-six male rats were assigned to six groups: normal control, venom control, venom plus antiserum, venom plus leaf extract (200 mg/kg), venom plus root extract (200 mg/kg), and venom plus combined extracts. After 14 days of treatment, blood samples were analyzed for white blood cells, red blood cells, haemoglobin, platelets, and haematocrit. Venom intoxication induced significant leukocytosis, anaemia, thrombocytopenia, and reduced haematocrit, whereas treatment with *L. lanceolata* extracts, particularly the root extract, significantly improved these parameters toward normal levels. The root extract restored white blood cells to $8.40 \pm 0.38 \times 10^9$/L, red blood cells to $7.65 \pm 0.30 \times 10^{12}$/L, haemoglobin to 6.80 ± 0.20 g/dL, platelets to $425.50 \pm 19.26 \times 10^9$/L, and haematocrit to $20.50 \pm 1.13\%$, indicating superior haematoprotective and anti-inflammatory effects relative to the leaf

AJBMBR Journal is licensed under a Creative Commons Attribution-NonCommercial-ShareAlike 4.0 International License

extract. Histological examination further confirmed these findings, showing that the extracts, especially the root, ameliorated venom-induced necrosis, hemorrhage, and congestion in liver and kidney tissues. These findings suggest that *Lophira lanceolata*, particularly its root extract, has therapeutic potential as a complementary intervention for managing snakebite-induced haematological disorders and tissue damage.

Keywords: *Bitis arietans*; Haematological Indices; *Lophira lanceolata*; Snakebite Envenomation; Wistar Rats

INTRODUCTION

Snakebite envenomation is a major global health concern, especially in tropical and subtropical areas where rural communities are frequently affected (Gutiérrez, 2021). Recognized as a neglected tropical disease, it causes high rates of illness and death, particularly in Africa, Asia, and Latin America (Yuniasih *et al.,*2020). The toxins in snake venom can cause severe health complications, especially in remote areas where access to modern healthcare is limited. Traditional medicine offers a unique perspective on the use of local remedies and practices that have been passed down through generations (Leonti, and Casu, 2013). Among traditional remedies for snakebites, the use of *Lophira lanceolata* (Ochnaceae family) stands out. Native to West and Central Africa, it is used in ethnomedicine to treat inflammation, infections, and snake poisoning (Lankoandé *et al.,*2017). Its bioactive components flavonoids, tannins, alkaloids, and phenolics have shown protective effects on the liver and kidneys in preclinical study (Ezea *et al.,*2023).

The haemotoxicity of viper venom is primarily mediated by enzymes such as snake venom metalloproteinases (SVMPs) and phospholipases A_2 (PLA_2s) (Gasanov *et al.,* 2014). These toxins induce a cascade of events leading to consumptive coagulopathy, haemorrhage, and platelet dysfunction, clinically manifested as prolonged clotting times, thrombocytopenia, and systemic bleeding (Alvitigala *et al.,* 2025). The profound systemic inflammatory response triggered by envenomation often results in significant leukocytosis (Ryan *et al.,* 2021). The resultant anaemia arises from both direct haemolysis and extravasation of blood due to capillary damage. These haematological alterations collectively contribute to hypovolemic shock, multi-organ failure, and increased mortality (Datta, 2015).

The cornerstone of treatment, antivenom immunoglobulin therapy, though life-saving, faces significant challenges including high cost, limited availability in endemic regions, risk of anaphylactic reactions, and poor efficacy against some venom-induced local tissue damage (Bermúdez-Méndez *et al.,* 2018). This therapeutic gap underscores the urgent need to investigate affordable, accessible, and effective complementary or alternative treatments, particularly from ethnomedicinal sources (Awoke and Cosendey,2025).

Lophira lanceolata Van Tiegh. ex Keay (Ochnaceae), commonly known as African sandalwood, is a medicinal plant widely used across West and Central Africa (Gbenou, 2023). In traditional medicine, decoctions or poultices from its leaves, bark, and roots are employed to treat various ailments, including inflammation, microbial infections, and notably, snakebite envenomation (Deshpande *et al.,* 2022). Phytochemical screenings have revealed that *L. lanceolata* is rich in bioactive compounds such as flavonoids, tannins, polyphenols, and alkaloids, which are known for their potent antioxidant, anti-inflammatory, and membrane-stabilizing properties (Sonter *et al.,* 2021). These properties are highly relevant for countering the oxidative stress, inflammation, and haemorrhagic pathology induced by snake venom. Preliminary ethnopharmacological reports suggest its efficacy, but systematic scientific validation, particularly regarding its effects on venom-induced haematological toxicity, is lacking.

Therefore, this study aimed to scientifically evaluate the protective and restorative effects of methanol leaf and root extracts of *Lophira lanceolata* on key haematological indices white blood cell count (WBC), red blood cell count (RBC), haemoglobin concentration (HGB), platelet count (PLT), and haematocrit (HCT) in a Wistar rat model of *Bitis arietans* venom-induced toxicity.

MATERIALS AND METHODS

Plant Material

Fresh leaves and roots of *Lophira lanceolata* were obtained from Jootar village in Ukum Local Government Area of Benue State, Nigeria. The leaves and roots were rinsed with water, air dried and then pulverized into fine powder using traditional mortar and pestle.

Extraction

Dried leaves and roots of *Lophira lanceolata* were separately ground into fine powder form using laboratory pestle and mortar and electric grinder. The finely ground powdered samples were packed into clean, dry sample containers and labelled appropriately and kept for further use. Extraction was carried out by the conventional solvent extraction method described by Umaru *et al.* (2019) with slight modification. Two hundred grams (200 g) of the pulverized leaf and root samples were separately weighed into clean plastic containers and soaked in 500 mL of ethanol (1:2.5 w/v). The mixtures were allowed to stand for 72 hours at room temperature with occasional shaking to facilitate extraction. thereafter, filtered with muslin cloth followed by Whatman No. 1 filter paper. The various extracts were evaporated to dryness with a rotary evaporator (BUCHI Operation India Private Limited, type: B-100HB, SN: 1500014189, 201) under increased pressure above 75°c to obtain the methanol crude extract. The dry weight and percentage yield of crude extract were determined. The various concentrates were transferred into air-tight containers and preserved in the refrigerator prior to administration. Before the administration, these were re-dissolved in distilled water.

Drugs and Chemicals

Bharat Serums and Vaccines (BSV) Snake venom Antiserum, methanol, chloroform, formalin. Distilled water was used in all preparations. All chemicals used were of analytical grade and supplied by reputable chemical manufacturers.

Experimental animals

Male Wistar rats weighing between 120 g and 200 g were used for this experiment. They were housed in standard cages with sawdust bedding at the Animal House Facility of the Department of Biochemistry, Faculty of Biosciences, Federal University Wukari. The rats were maintained under a 12 h light/12 h dark cycle at a controlled room temperature of 25 ± 3 °C, with free access to standard laboratory feed and clean water.

Experimental design

Thirty-six male wistar rats were used for this experiment. The animals were acclimatized for two weeks before the experiment before the commencement of the experiment and divided into groups as shown: Group 1 received normal saline (served as normal control), Group 2 received no treatment (served as negative control), Group 3

received BSV snake venom anti serum (served as Positive control), Group 4 were administered with 200 mg/*kg Lophira lanceolata* leaf extracts, Group 5 were administered with 200 mg/*kg Lophira lanceolata* root extracts, and Group 6 were administered with a combination of leaf and root extract.

Hematological assessment

The determinations of haematological parameters were carried out using automated haematology analyser (Agile S30 haematology autoanalyzer V2.0, China). Using whole blood, the total red blood cell (RBC) count, haemoglobin (HB) concentration, packed cell volume (PCV), white blood cell (WBC) count and platelet count were determined.

Histopathological examination

This was done according to the methods of Choji *et al.* (2015) and Avwioro, (2011). Tissues were harvested and fixed in 10% formalin for 3 days, cut into thin slices of 5mmX 2mm X 1mm thick and then processed. Tissues were embedded in molten paraffin wax using embedding moulds. The tissues were embedded using embedding cassettes on a tissue Tek Embedding Centre and cooled rapidly on the cooling component. Tissues were sectioned using a rotary microtome set at 4 micromes, picked on slides and ready for staining. Sections were dewaxed and hydrated by passing through two changes of xylene and through descending grades of alcohol (100%, 80%, 70%) for three minutes each and then into water, stained in Harris' haematoxylin solution for 5 minutes and washed in running water. They were differentiated in 1% acid alcohol and then washed well in water, blued in Scott's tap water substitute for 5 minutes and rinsed briefly in distilled water, counterstained in 1% aqueous eosin for 2 minutes, washed well in water, dehydrated in descending grades of alcohol, cleared in xylene and mounted in DPX (Destrene, plasticiser and xylene). Sections were then placed in slide carriers and placed in a 400°C oven to dry overnight. They were read microscopically at the magnifications of X100 and X400.

Data Analysis

Statistical Package for Social Sciences (SPSS) version 23 was used for this analysis. Statistical analysis was carried out using one-way Analysis of Variance (ANOVA) followed by Duncan multiple comparison test. The results were expressed as Mean ± standard deviation (SD). ($n = 5$) with $p < 0.05$ being statistically significant.

RESULTS

Table 1: Levels of Selected Haematological Indices in Snake Venom-Induced Toxicity Wistar Rats Administered with *Lophira lanceolata* Methanol Leaf and Root Extracts.

Groups	WBC (10^9/L)	RBC (10^{12}/L)	HGB (g/dL)	PLT (10^9/L)	HCT (%)
One (Normal control)	7.80 ± 0.42^{ab}	8.12 ± 0.31^{ab}	7.20 ± 0.30^{c}	460.14 ± 25.30^{d}	22.34 ± 1.22^{c}
Two (Negative control: 0.8 mg/kg snake venom)	13.90 ± 0.60^{cd}	4.25 ± 0.22^{a}	5.60 ± 0.35^{a}	190.00 ± 18.30^{a}	16.50 ± 1.13^{a}
Three (Positive control: 0.8 mg/kg snake venom + BSV snake venom antiserum)	8.10 ± 0.45^{b}	7.98 ± 0.28^{ab}	6.80 ± 0.20^{b}	445.20 ± 22.00^{cd}	20.48 ± 1.50^{b}
Four (0.8 mg/kg snake venom + 200 mg/kg leaf extract)	10.20 ± 0.51^{c}	6.25 ± 0.26^{a}	6.58 ± 0.33^{ab}	320.26 ± 20.50^{b}	19.78 ± 1.24^{ab}
Five (0.8 mg/kg snake venom + 200 mg/kg root extract)	8.40 ± 0.38^{b}	7.65 ± 0.30^{ab}	6.80 ± 0.20^{b}	425.50 ± 19.26^{c}	20.50 ± 1.13^{b}
Six (0.8 mg/kg snake venom + 200 mg/kg leaf extract + 200 mg/kg root extract)	9.15 ± 0.50^{c}	7.10 ± 0.34^{b}	6.70 ± 0.36^{ab}	398.72 ± 21.08^{bc}	20.10 ± 1.14^{ab}

Results are expressed as mean ± standard deviation of group results obtained (n=6).

Mean values ± standard deviation in the same column with different letters of the alphabets (a, b, c, d, e, f), as superscript show statistically significant difference ($p<0.05$)

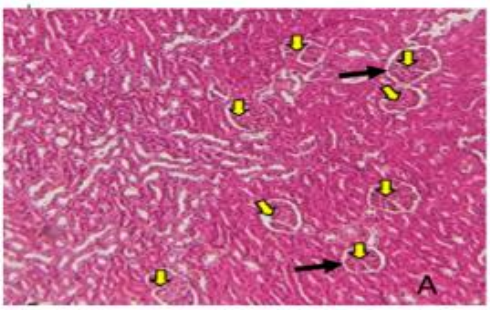

Figure 4.1 (Plate 1/Group1): Light Photomicrograph of male wistar rats Kidney exposed to normal environmental and nutritional condition, showing normal architecture as shown by intact glomeruli (yellow arrow) HandE X 100.

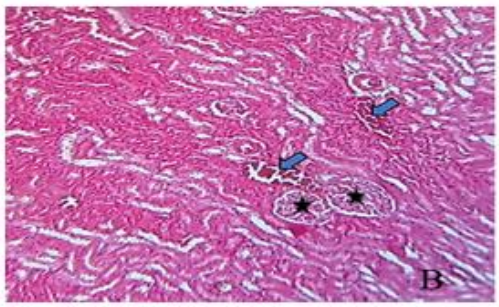

Figure 4.2 (Plate2/Group2): Photomicrograph of kidney section of wistar rats in group 2 induced with 0.8 mg/kg snake venom showing changes of the renal histomorphology. There were evidences of severe congestion of the renal blood vessels (blue arrows) and glomeruli (black stars). Stain: H & E; Mag: x100.

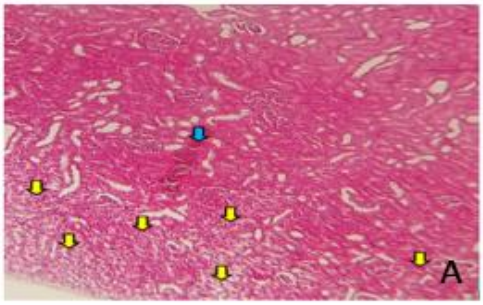

***Figure* 4.3 (Plate 3):** Photomicrograph of kidney section of wistar rats in group 3 induced with 0.8 mg/kg body weight of snake venom and treated with 1.25 mL/kg BSV snake venom antiserum showing necrosis of the kidney tubules (yellow arrows) and renal corpuscles. Stain: H & E; Mag: x100.

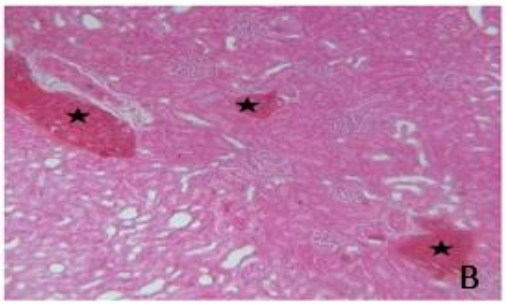

***Figure* 4.4 (Plate 4):** Photomicrograph of kidney section of wistar rats in group 4 induced with 0.8 mg/kg body weight of snake venom and treated with 200 mg/kg body weight of methanol leaf extract of *Lophira lanceolata* showing congestion of the renal blood vessels (black stars) is observed. Stain: H & E; Mag: x100.

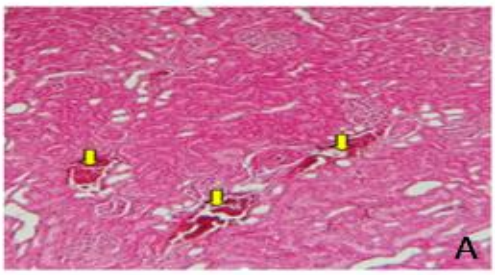

***Figure* 4.5 (Plate 5):** Photomicrograph of kidney section of wistar rats in group 5 induced with 0.8 mg/kg body weight of snake venom and treated with 200 mg/kg body weight of methanol root extract of *Lophira lanceolata* revealing severe congestion of the renal blood vessels (yellow arrows). Some of the glomeruli were shrunken. Stain: H & E; Mag: x100.

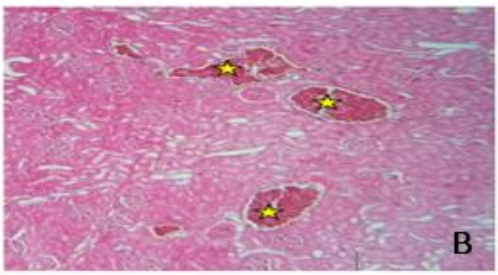

***Figure* 4.6 (Plate 6):** Photomicrograph of kidney section of wistar rats in group 6 induced with 0.8 mg/kg body weight of snake venom and treated with 200 mg/kg body weight of methanol extract of both leaf and root of *Lophira lanceolata* revealing severe congestion of the renal blood vessels and moderately altered glomeruli (yellow stars). Stain: H & E; Mag: x100.

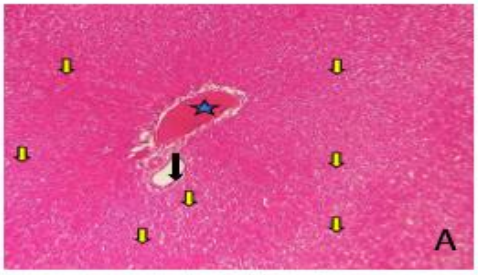

***Figure* 4.7 (Plate 7):** Photomicrograph of liver section from control rat (Group 1) showing normal showing normal morphology. The hepatocytes are intermingled by hepatic sinusoids (yellow arrows) which are linked into the central vein (blue stars) and the nuclei (black arrow). Stain: H & E; Mag: x100.

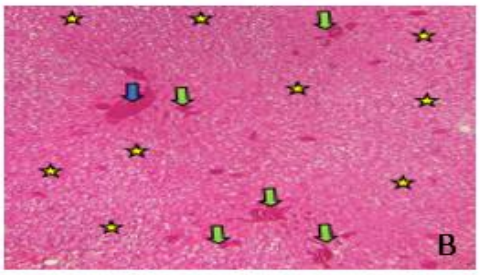

***Figure* 4.8 (Plate 8):** Photomicrograph of liver section of wistar rats in group 2 induced with 0.8 mg/kg body weight showing severe congestion of the central vein (blue arrow). There is severe necrosis of some of the hepatocytes (yellow stars) and haemorrhage (green arrows). Stain: H & E; Mag: x100.

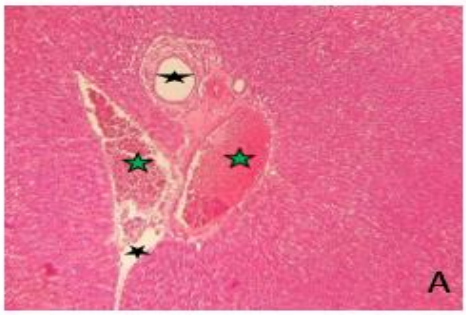

***Figure* 4.9 (Plate 9):** Photomicrograph of liver section of wistar rats in group 3 induced with 0.8 mg/kg body weight of snake venom and treated with 1.25 mL/kg BSV snake venom antiserum showing congestion of the portal veins (green stars) and peri-portal region. Some degenerating hepatocytes are evident. Stain: H & E; Mag: x400.

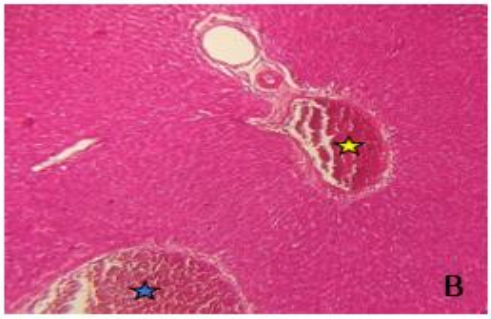

***Figure* 4.10 (Plate 10):** Photomicrograph of liver section of wistar rats in group 4 induced with 0.8 mg/kg body weight snake venom and treated with 200 mg/kg body weight of methanol leaf extract of *Lophira lanceolata* showing severe congestion of the portal vein (yellow star) and central vein (blue star) which also appeared enlarged. Some degenerating hepatocytes are evident. Stain: H & E; Mag: x100.

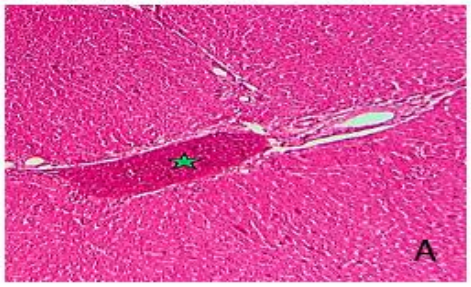

***Figure* 4.11 (Plate 11):** Photomicrograph of liver section of wistar rats in group 5 induced with 0.8 mg/kg body weight snake venom and treated with 200 mg/kg body weight of methanol root extract of *Lophira lanceolata* showing degenerating hepatocytes and severe congestion of the portal veins (green stars). Stain: H & E; Mag: x100.

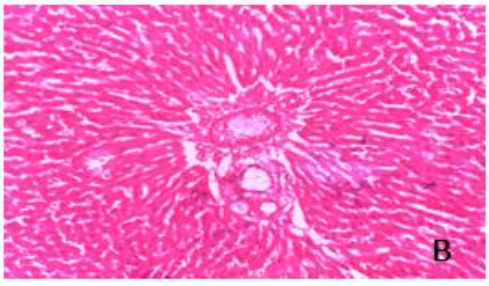

***Figure* 4.12 (Plate 12):** Photomicrograph of liver section of wistar rats in group 6 induced with 0.8 mg/kg body weight of snake venom and treated with 200 mg/kg body weight of methanol extract of both leaf and root of *Lophira lanceolata* showing severe congestion of the portal vein and degenerating hepatocytes. Stain: H & E; Mag: x400

DISCUSSION

Snakebite envenomation continues to be a major health problem across the world, affecting millions every year and causing many deaths (Bawaskar *et al.,*2021). The World Health Organization (WHO) launched an initiative in 2019 to reduce snakebite-related deaths and disabilities by 50% by 2030. As part of the global search for effective treatments, medicinal plants have drawn attention for their potential antivenom properties.

The White Blood Cell (WBC) count is a crucial indicator of the immune system's status and inflammatory response. In the negative control group (venom-only), the WBC count was significantly elevated ($13.90 \pm 0.60\times10^9$/L) compared to the normal control ($7.80 \pm 0.42\times10^9$/L). This leukocytosis is a classic physiological response to envenomation, as snake venoms often contain toxins that trigger a massive inflammatory cascade, recruiting immune cells to the site of injury and into the systemic circulation. The implication is that the body is mounting a defensive reaction against the venom's cytotoxic and necrotic components. Treatment with both plant extracts demonstrated a notable anti-inflammatory effect. The leaf extract (Group 4) reduced WBC to 10.20×10^9/L, while the root extract (Group 5) and the combination (Group 6) brought it down to 8.40 and 9.15×10^9/L, respectively. The root extract's performance was particularly remarkable, normalizing the WBC count to a value statistically indistinguishable from the normal and positive control (antiserum) groups. This pattern of venom-induced leukocytosis followed by extract-mediated normalization aligns with findings from other studies on medicinal plants. Research on *Mucuna pruriens* and *Andrographis paniculata* extracts against snake venom showed a similar capacity to suppress elevated WBC counts, attributed to the inhibition of pro-inflammatory cytokines like TNF-α and IL-6 (Rao *et al.,*2024). The superior efficacy of the root extract of *Lophira lanceolata* suggests it may possess more potent bioactive compounds, such as flavonoids or saponins, known for their immunomodulatory and anti-inflammatory properties. This positions the root extract as a promising candidate for mitigating the severe inflammatory burden associated with snakebite envenomation, potentially reducing secondary tissue damage.

The Red Blood Cell (RBC) count and Hemoglobin (HGB) concentration are primary indicators of the blood's oxygen-carrying capacity, and their reduction signifies anemia (Linklater and Higgs, 2016). Envenomation in the negative control group caused a drastic fall in RBC ($4.25 \pm 0.22\times10^{12}$/L) and HGB ($5.60 \pm 0.35$ g/dL) compared to the

normal control (RBC: 8.12; HGB: 7.20). This is a direct consequence of hemorrhagic toxins in the venom, such as metalloproteinases and haemorrhagins, which damage the endothelium of blood vessels and cause extravasation of blood, leading to hemorrhagic anemia. The significant drop in HGB directly implies a reduced oxygen delivery to tissues, which can lead to hypoxia and organ dysfunction. Treatment with the extracts, especially the root extract (Group 5), effectively reversed this trend, raising RBC to 7.65×10^{12}/L and HGB to 6.80 g/dL, values that are very close to the normal and positive controls, indicating a strong haemoprotective effect. The root extract restored RBC levels close to normal, performing almost as well as antivenom. The combined extract also improved RBC counts but less than the root alone, while the leaf extract had only mild effects (Nnadiukwu *et al.,*2024). The root extract restored HGB to near-normal, showing its role in limiting red cell destruction and supporting production (Okoye, *et al.,*2025). The ability of plant extracts to counteract venom-induced haemorrhage and anemia has been documented in other scientific investigations. Studies on plants like *Eclipta prostrata* and *Tamarinthus indica* have shown that their extracts can inhibit venom phospholipases A2 and metalloproteinases (Singh *et al.,* 2020; Leskovac, 2023), thereby preserving vascular integrity and preventing RBC loss. The near-complete restoration of RBC and HGB by the root extract of *Lophira lanceolata* suggests a similar mechanism of action, possibly through the direct neutralization of venom toxins or by stabilizing capillary membranes.

Platelets (PLT) are essential for hemostasis, and their count can be dramatically affected by snake venoms. The envenomation (Group 2) caused a severe thrombocytopenia, with platelet counts plummeting to $190.00 \pm 18.30\times10^{9}$/L from a normal of 460.14. This is a common effect of venoms that contain toxins which either directly aggregate platelets (consuming them) or activate the coagulation cascade, leading to disseminated intravascular coagulation (DIC) and platelet depletion. The clinical implication is a high risk of uncontrolled bleeding. All treatment groups showed a significant recovery in platelet counts. The leaf extract (Group 4) increased PLT to 320.26, the root extract (Group 5) to 425.50, and the combination (Group 6) to 398.72×10^{9}/L, with the root extract again showing the most potent restorative effect, nearly matching the positive control. Among the plant extracts, the leaf had the strongest effect in lowering platelets, possibly promoting vascular repair (Sharifi-Rad *et al.,*2022). The mechanism is often linked to compounds that inhibit venom enzymes responsible for platelet activation or aggregation. The fact that *Lophira lanceolata* root extract was able to restore platelet

counts so effectively suggests it may contain molecules that protect platelets from uncontrolled activation or promote thrombopoiesis. Commercial antivenoms are not always effective at reversing venom-induced coagulopathies and thrombocytopenia, and this finding highlights the potential of this plant extract as an adjunct therapy.

Hematocrit (HCT) represents the volume percentage of red blood cells in blood and is another key marker for anemia and hemoconcentration or hemodilution. The negative control group exhibited a significant decrease in HCT (16.50 ± 1.13%) compared to the normal control (22.34%). This finding is consistent with the observed anemia (low RBC and HGB), as the loss of red blood cells through haemorrhage directly reduces the proportion of cellular components in the blood. The implication is a confirmation of the blood loss and dilutional effect following vascular damage. Treatment with the extracts led to a dose-dependent recovery of HCT levels. The root extract (Group 5) was the most effective, restoring HCT to 20.50%, a value very close to the normal and positive control groups, indicating a successful reversal of the anemic state. The correlation between improved HCT and treatment with anti-venom botanicals has been observed in parallel research. A study on Annona senegalensis against *Echis carinatus* venom showed a similar normalization of HCT levels in treated animals (Emmanuel *et al.,*2014). The restoration of HCT by *Lophira lanceolata* root extracts reinforces the data from RBC and HGB, providing a cohesive picture of its haemoprotective efficacy. It confirms that the extract doesn't just increase hemoglobin synthesis but also supports the overall restoration of the red cell mass.

Histological results showed that venom-only rats had severe liver damage, including blood vessel congestion, cell death, and bleeding similar to reports by Khalil *et al.* (2018). Antivenom-treated rats had less damage, but some problems remained (Pipelzadeh *et al.,*2015). The liver from the venom-control group (Group 2, Figure 4.8) displays severe pathology, including congestion of the central vein, widespread necrosis of hepatocytes, and hemorrhage. This indicates that the venom's cytolytic and hemotoxic components cause direct damage to liver cells and disrupt the hepatic vascular system, compromising the organ's metabolic and detoxification functions. The normal liver architecture seen in the healthy control (Group 1, Figure 4.7) starkly contrasts with this, highlighting the extent of the venom-induced injury. The leaf extract also helped, though less so (Del Prete *et al.,*2012). The combined extract gave intermediate results, possibly due to compound interactions (Ncube *et al.,*2012).

In the kidneys, venom caused tubular and glomerular damage, supporting findings from Sitprija and Sitprija. (2021). Antivenom reduced the injury but did not completely reverse it (de Silva *et al.,*2016). The kidney section from the venom-only control group (Group 2, Figure 4.2) shows significant architectural damage, characterized by severe congestion of renal blood vessels and glomeruli. This indicates impaired blood flow and acute inflammatory response, leading to potential renal failure, a common consequence of envenomation by vipers like *Echis carinatus*. The damage is so profound that even the standard antiserum treatment (Group 3, Figure 4.3) could not fully prevent it, as evidenced by the presence of necrotic tubules and renal corpuscles. This suggests that while the antiserum neutralizes circulating toxins, it may not fully repair existing tissue damage or prevent secondary inflammatory injury. The root extract provided the best kidney protection, followed by the leaf. The combined extract showed mixed outcomes, again likely due to interactions between plant compounds (Ncube *et al.,*2012).

While the leaf extract (Group 4) and the combination therapy (Group 6) still showed significant vascular congestion in both kidney and liver tissues, the root extract appeared to mitigate some of the most severe damage. Although congestion was still present in the root extract group, the absence of reported widespread necrosis or hemorrhage in the liver, as seen in the venom-control and even the antiserum group, is a notable finding. This implies that the root extract may contain potent bioactive compounds that help stabilize cell membranes or protect parenchymal cells from the cytolytic effects of the venom, thereby preserving organ function more effectively (Roy and Bharadvaja, 2021). The antiserum (Group 3) reduced some aspects of toxicity but failed to prevent necrosis in the kidney and degeneration in the liver. The histological profile of the root extract group is not worse than that of the antiserum group and, in some aspects like hepatocyte preservation, may even be comparable or superior. This suggests that *Lophira lanceolata*, particularly its root, could be a valuable source of complementary therapeutic agents that target tissue repair and cytoprotection, mechanisms that may not be the primary function of antivenom serums. The persistence of vascular congestion across most treatment groups indicates that reversing hemodynamic disturbances is challenging (Boorsma *et al.,*2020). However, the more critical finding is the apparent ability of the root extract to limit direct cellular necrosis.

CONCLUSION

The methanol extracts of *Lophira lanceolata* leaf and root possess significant protective effects against *Bitis arietans* venom-induced toxicity in Wistar rats. The administration of these extracts successfully ameliorated the haematological disturbances caused by envenomation, restoring white and red blood cell counts, haemoglobin, and platelet levels. Furthermore, Histopathological examination of the liver and kidney tissues provided conclusive structural evidence, showing that the extracts, particularly the root extract, preserved cellular architecture and mitigated venom-induced damage like necrosis and hemorrhage. Therefore, the root extract of *Lophira lanceolata* exhibits superior efficacy compared to the leaf extract, validating its traditional use and positioning it as a promising candidate for adjunct therapy in snakebite envenomation

Authors' Contributions

In view of the findings from this present study, the following are some contribution to knowledge;

i. This study provides a comprehensive experimental evidence validating the traditional use of *Lophira lanceolata* against snakebite envenomation and demonstrates its efficacy against the cytotoxic and systemic effects of *Bitis arietans* venom.
ii. The research establishes a clear distinction in the bioactivity of different plant parts, revealing that the methanol root extract of *Lophira lanceolata* possesses significantly superior haematorestorative properties compared to the leaf extract when administered at an equal dose of 200 mg/kg.
iii. The histological findings provide crucial morphological corroboration, confirming for the first time that pre-treatment with *Lophira lanceolata* root extract effectively preserves the cellular architecture of the liver and kidney against venom-induced necrosis, hemorrhage, and congestion.

Acknowledgments

The authors would like to thank Mr. Philip Shadrach of Biochemistry Department, Federal University Wukari, Taraba State, Nigeria, for technical assistance in animal handling. This study did not receive any funding from any private or governmental organization.

REFERENCES

Ahoton, D., Assogba, M. F., Davo, A., Toklo, P. M., Houndjo, C. F., Yayi Ladekan, E. C., Moudachirou, M., & Gbenou, J. D. (2023). Anti-inflammatory activities of aqueous and ethanolic extracts of *Lophira lanceolata*'s Van Tiegh. ex Keay (Ochnaceae) leaves. *Journal of Pharmacognosy and Phytochemistry, 12*(6), 202–209. https://doi.org/10.22271/phyto.2023.v12.i6c.14781

Alvitigala, B. Y., Dissanayake, H. A., Weeratunga, P. N., Padmaperuma, P. A. C. D., Gooneratne, L. V., & Gnanathasan, C. A. (2025). Haemotoxicity of snakes: A review of pathogenesis, clinical manifestations, novel diagnostics and challenges in management. *Transactions of The Royal Society of Tropical Medicine and Hygiene, 119*(3), 283–303. https://doi.org/10.1093/trstmh/trae058

Awoke, A., & Cosendey, B. N. (2025). Investigate the ethnomedical practices of different indigenous communities: A literature review. *International Journal of Ethnoscience and Technology in Education, 2*(1), 64–89. https://doi.org/10.33394/ijete.v2i1.13903

Bermúdez-Méndez, E., Fuglsang-Madsen, A., Føns, S., Lomonte, B., Gutiérrez, J. M., & Laustsen, A. H. (2018). Innovative immunization strategies for antivenom development. *Toxins, 10*(11), 452. https://doi.org/10.3390/toxins10110452

Boorsma, E. M., ter Maaten, J. M., Damman, K., Dinh, W., Gustafsson, F., Goldsmith, S. R., & Voors, A. A. (2020). Congestion in heart failure: A contemporary look at physiology, diagnosis and treatment. *Nature Reviews Cardiology, 17*(10), 641–655. https://doi.org/10.1038/s41569-020-0379-7

Datta, P. K. (2015). Shock and blood transfusion. In *MCQs and EMQs in surgery: A Bailey & Love revision guide* (2nd ed., pp. 9–17). CRC Press.

de Silva, H. A., Ryan, N. M., & de Silva, H. J. (2016). Adverse reactions to snake antivenom, and their prevention and treatment. *British Journal of Clinical Pharmacology, 81*(3), 446–452. https://doi.org/10.1111/bcp.12739

Del Prete, A., Scalera, A., Iadevaia, M. D., Miranda, A., Zulli, C., Gaeta, L., & Loguercio, C. (2012). Herbal products: Benefits, limits, and applications in chronic liver disease. *Evidence-Based Complementary and Alternative Medicine, 2012*, Article 837939. https://doi.org/10.1155/2012/837939

Deshpande, A. M., Sastry, K. V., & Bhise, S. B. (2022). A contemporary exploration of traditional Indian snake envenomation therapies. *Tropical Medicine and Infectious Disease, 7*(6), 108. https://doi.org/10.3390/tropicalmed7060108

Emmanuel, A., Ebinbin, A., & Amlabu, W. (2014). Detoxification of *Echis ocellatus* venom-induced toxicity by *Annona senegalensis* Pers. *Journal of Complementary and Integrative Medicine, 11*(2), 93–97. https://doi.org/10.1515/jcim-2012-0058

Ezea, O. C., Nwachukwu, M. O., Nnodim, N. N., Nwachukwu, C. N., Ozioko, K. U., & Azorji, J. (2023). Gametocyte dynamics and the effects of aqueous and ethanolic leaf extracts of *Lophira lanceolata* in mice infected with *Plasmodium bergei*. *Journal of Experimental and Molecular Biology, 24*(1), 7–28. https://doi.org/10.47743/jemb-2023-70

Gasanov, S. E., Dagda, R. K., & Rael, E. D. (2014). Snake venom cytotoxins, phospholipase A2s, and Zn2+-dependent metalloproteinases: Mechanisms of action and pharmacological relevance. *Journal of Clinical Toxicology, 4*(1), Article 1000181. https://doi.org/10.4172/2161-0495.1000181

Gutiérrez, J. M. (2021). Snakebite envenomation as a neglected tropical disease: New impetus for confronting an old scourge. In S. P. Mackessy (Ed.), *Handbook of venoms and toxins of reptiles* (2nd ed., pp. 471–483). CRC Press.

Khalil, A. M., Wahsha, M. A., Khadra, K. M. A., Khalaf, M. A., & Al-Najjar, T. H. (2018). Biochemical and histopathological effects of the stonefish (*Synanceia verrucosa*) venom in rats. *Toxicon, 142*, 45–51. https://doi.org/10.1016/j.toxicon.2017.12.052

Lankoandé, B., Ouédraogo, A., Boussim, J. I., & Lykke, A. M. (2017). Natural stands diversity and population structure of *Lophira lanceolata* Tiegh. ex Keay, a local oil tree species in Burkina Faso, West Africa. *Agroforestry Systems, 91*(1), 85–96. https://doi.org/10.1007/s10457-016-9913-3

Leonti, M., & Casu, L. (2013). Traditional medicines and globalization: Current and future perspectives in ethnopharmacology. *Frontiers in Pharmacology, 4*, Article 92. https://doi.org/10.3389/fphar.2013.00092

Leskovac, A. (2023). Natural inhibitors of phospholipase A2: Current knowledge and therapeutic approaches. In S. Chakraborti (Ed.), *Phospholipases in physiology and pathology* (Vol. 5, pp. 67–77). Elsevier. https://doi.org/10.1016/B978-0-323-95699-4.00015-3

Linklater, A., & Higgs, V. (2017). Red blood cells and hemoglobin. In R. Kirby & A. Linklater (Eds.), *Monitoring and intervention for the critically ill small animal: The rule of 20* (pp. 157–176). John Wiley & Sons. https://doi.org/10.1002/9781118923870.ch10

Ncube, B., Finnie, J. F., & Van Staden, J. (2012). In vitro antimicrobial synergism within plant extract combinations from three South African medicinal bulbs. *Journal of Ethnopharmacology, 139*(1), 81–89. https://doi.org/10.1016/j.jep.2011.10.025

Pipelzadeh, M. H., Jalali, A., Dezfulian, A. R., Khorasgani, Z. N., Sarvestani, S., Ghalambor, A. H., & Azarpanah, A. (2015). A forward to optimization of antivenom therapy: An in vivo study upon the effectiveness of the antivenom against early and delayed nephrotoxicity induced by the venom of the Iranian scorpion *Hemiscorpius lepturus* in rat. *Toxicon, 100*, 13–19. https://doi.org/10.1016/j.toxicon.2015.03.023

Rao, S., Reghu, N., Nair, B. G., & Vanuopadath, M. (2024). The role of snake venom proteins in inducing inflammation post-envenomation: An overview on mechanistic insights and treatment strategies. *Toxins, 16*(12), 519. https://doi.org/10.3390/toxins16120519

Roy, A., & Bharadvaja, N. (2021). Venom-derived bioactive compounds as potential anticancer agents: A review. *International Journal of Peptide Research and Therapeutics, 27*(1), 129–147. https://doi.org/10.1007/s10989-020-10073-z

Ryan, R. Y. M., Seymour, J., Loukas, A., Lopez, J. A., Ikonomopoulou, M. P., & Miles, J. J. (2021). Immunological responses to envenomation. *Frontiers in Immunology, 12*, 661082. https://doi.org/10.3389/fimmu.2021.661082

Sharifi-Rad, J., Quispe, C., Shaheen, S., El Haouari, M., Azzini, E., Butnariu, M., & Calina, D. (2022). Flavonoids as potential anti-platelet aggregation agents: From biochemistry to health promoting abilities. *Critical Reviews in Food Science and Nutrition, 62*(29), 8045–8058. https://doi.org/10.1080/10408398.2021.1924612

Singh, P., Yasir, M., Khare, R., Tripathi, M. K., & Shrivastava, R. (2020). Snake venom phospholipase A2 and its natural inhibitors. *Natural Product Sciences, 26*(3), 259–267. https://doi.org/10.20307/nps.2020.26.3.259

Sitprija, V., & Sitprija, S. (2012). Renal effects and injury induced by animal toxins. *Toxicon, 60*(5), 943–953. https://doi.org/10.1016/j.toxicon.2012.06.012

Sonter, S., Mishra, S., Dwivedi, M. K., & Singh, P. K. (2021). Chemical profiling, in vitro antioxidant, membrane stabilizing and antimicrobial properties of wild growing *Murraya paniculata* from Amarkantak (M.P.). *Scientific Reports, 11*(1), 9691. https://doi.org/10.1038/s41598-021-87404-7

Umaru, I. J., Badruddin, F. A., & Umaru, H. A. (2019). Phytochemical screening and antimicrobial activity of *Lophira lanceolata* extracts. *Journal of Medicinal Plants Research, 13*(5), 112–118.

Yuniasih, D., Tejosukmono, A., & Heriyanto, J. (2020). Snakebite as a neglected tropical diseases in Indonesia: A review. *International Journal of Scientific & Technology Research, 9*(3), 6180–6185.