African Journal of
Biochemistry and Molecular Biology Research

ISSN : 1595-7926

Index: Harvard, Boston, Sydney University, Dimensions, Lens, ResearchGet Scilit, Semantic, Google Scholar, Base etc

https://doi.org/10.58578/AJBMBR.v2i2.5424

Biosafty Evaluation of "Makann" A Bi-herbal Formulation on Female Mice: Kidney and Liver

Anne Oghenekevwe Itemire[1], MacDonald Idu[2], Bafor Evi Enitome[3], Gerald Ikechi Eze[4], Benjamin Ogunma Gabriel[5]
University of Benin, Edo State. Nigeria
anne.itemire@uiben.edu

Article Info:

Submitted:	Revised:	Accepted:	Published:
Mar 17, 2025	Apr 1, 2025	Apr 13, 2025	Apr 18, 2025

Abstract

This study evaluated the biosafety of "Makann", a bi-herbal formulation (*Garcinia kola* and *Carica papaya*), on the kidneys and liver of female mice. The collected, washed, shade-dried and processed plant extract (the biherbal formulation) was administered in various groups of female mice at 2 g/kg as a single dose for 24 hours and 14 days, and 14 days daily dose, focusing on body weight, temperature, haematological parameters, organ weight, and histology of the organs using standard analytical methods. The results indicated the biherbal formulated extract at 2 g/kg had no significant difference in the body weight and temperature of the treated animals across single doses of 24 hr and 14 days and 14 daily doses when compared with the control. There was a significant increase in white blood cell count, lymphocyte count, red blood cell count, hemoglobin level, and mean corpuscle hemoglobin concentration in the 24-hr single-dose treated group. Platelet count was significantly increased in all treatment groups compared with the control ($p<0.05$). The effects of the biherbal extract showed no significant difference in organ weights (liver and kidney) in single doses of 24 hr and 14 days, and daily doses of 14 days when compared with the control groups ($p<0.05$). The histopathological evaluation of the understudied vital

AJBMBR Journal is licensed under a Creative Commons Attribution-NonCommercial-ShareAlike 4.0 International License

organs revealed no lesions or signs of hepatorenal toxicity across the treatment groups when compared with the control. The insignificant toxicity observed in the biherbal formulation across the studied parameters suggested that the biherbal formulation may exhibit less or no toxicity at the studied dose of 2000 mg/kg. In conclusion, the biherbal formulation may be used at 2 g/kg for safety purposes; further studies on its safety at long-term and other dose administrations should be carried out.

Keywords: Biosafety, Bi-herbal formulation, Garcinia kola, Carica papaya, Hepatorenal toxicity, Histopathology, Mice study, Herbal safety, Acute toxicity, Subacute toxicity, Makann formulation

INTRODUCTION

Plants have historically served as sources of remedies for various diseases across all continents, particularly in Africa, which boasts a rich cultural heritage and a wide array of traditional medicine practices dating back to ancient times. Many nations in Africa depend on folk medicine to fulfill their healthcare needs (Teh *et al.,* 2022; Lim *et al.*, 2021). In the Ilaje community of Ondo State, Nigeria, for instance, the root of *Garcinia kola* is utilized to treat appendicitis. Due to the high cost of new pharmaceuticals, about 80% of the population in many West African countries turned to medicinal plants for treatment (Teng *et al.*, 2019; Sobia *et al.*, 2016).

Garcinia kola, commonly known as bitter kola, male kola, and false kola, belongs to the Guttifera family. In Nigeria, it is referred to by various names, including Orogbo (Yoruba), Cida goro (Hausa), Aku ilu or Ugugolu (Igbo), Efiari (Efik), and Igoligo (Idoma). This medium-sized evergreen tree typically reaches heights of 13 to 15 meters and thrives in moist forests, found naturally in Sierra Leone, Angola, and Nigeria. *Garcinia kola* is reputed to help manage liver disorders, diarrhea (Sheneni *et al.*, 2018; Nariya ans Jhala, 2017; Sathyapalan *et al.*, 2020), diabetes, bronchitis, throat infections, and is also used as an aphrodisiac (Longdet and Adoga, 2017). Traditionally, the root is employed as a remedy for coughs and appendicitis (data unpublished). Despite its widespread use in tropical Africa, there is a lack of scientific literature evaluating the toxicological effects of its root.

Carica papaya belongs to the family Caricaceae, and it is predominantly grown for its fruit; and its young leaves are consumed as a vegetable. Various parts of the plant have been traditionally utilized for medicinal purposes to manage health issues (WHO, 2019). The

juice from the green leaves is consumed to treat malaria-related fevers. The leaves are utilized for digestive disorders and other gastrointestinal issues. The fruit is used to alleviate high fever, cough, and lack of appetite, while the seeds are known for treating digestive problems, enhancing protein digestion, and expelling intestinal parasites. The root of the plant is employed to address urinary issues, and the bark is used for toothaches (Phromnoi *et al*., 2022). Various studies have been conducted to investigate the biological effects of different parts of *C. papaya.* The fruit and seeds exhibit bacteriostatic properties against various enteropathogenic bacteria in humans. Research indicated that diabetic rats with experimentally induced wounds showed notable healing after receiving an aqueous extract of *C. papaya* fruit (Subramanian *et al*., 2018).

Medicinal plants often contain various pharmacologically active compounds that can enhance health either on their own, in combination, or synergistically (Jitareanu *et al*., 2023). The extraction of phytochemicals from these plants, which could lead to significant therapeutic drugs in modern medicine, has sparked continued interest in assessing natural products derived from plants as viable chemotherapeutic agents (Rahmat and Damon, 2018). Plants generate bioactive compounds as a defensive mechanism against herbivores, but these compounds can also possess toxic properties (Gadhwal *et al*., 2016). The growing interest in medicinal plants necessitates more thorough scientific research into their efficacy and possible toxic effects. Investigating the toxicity of medicinal plants is crucial not only for enhancing traditional medicine but also for the development of new therapeutic agents (Nair and Jacob, 2016). Recently, concerns have been raised about the insufficient quality control and lack of scientific backing regarding the safety and effectiveness of natural products derived from plants (Balekundi and Mannur, 2020). Consequently, evaluating the toxicity of these plants and ensuring their safety has become a vital ethical concern.

MATERIALS AND METHODS

Plant Material and Authentication

Garcinia kola and *Carica papaya* roots were harvested from Ovia North East Local Government Area of Edo State in the month of November. The samples were authenticated in the Department of Plant Biology and Biotechnology, Faculty of Life Sciences, University of Benin, Benin City, Edo State and were allotted voucher specimen numbers; *Garcinia kola* UBH-365 and *Carica papaya* UBH-C505.

Plant Extraction

The roots of the two plants were properly rinsed, cut into small pieces and dried in the shade for two weeks. The dried roots were further dried in hot air oven at 60 °C for 6 hr before being pulverised separately into powder using a laboratory milling machine. *Garcinia kola* (50 g) and *Carica papaya* (50 g) roots were combined (100 g) and was macerated in boiled water and absolute methanol. They were left at room temperature (30 °C ± 2 °C) with frequent shaking for 72 hr. They were filtered using a glass funnel tightly plugged with cotton wool, and the filtrates were concentrated in a laboratory hot air oven at 60 °C. They were properly labeled and kept in the refrigerator at 4 °C for use.

Experimental Animals

Albino adult female mice weighing 20 – 30 g were used. The animals were maintained at the Animal Unit of the Department of Pharmacology and Toxicology, Faculty of Pharmacy, University of Benin, Benin City, Edo State, Nigeria. Ethical approval (EC/FP/021/20) was obtained from the Ethics Committee on the Use of Animals for Experimental Procedures, Faculty of Pharmacy, University of Benin. The animals were housed in well-ventilated cages and fed with commercial pelleted feed with free access to clean water *ad libitum*. All animals were handled carefully following the Guide for the Care and Use of Laboratory Animals (2011). All animals were weighed on S-Mettler electronic compact balance model K- 500BH (max=500, d=0.01g), weight was recorded in grams. Anal temperature was taken using C-Tone digital thermometer (Mode: GF502) in degree Celsius (°C).

Acute Toxicity

The modified method of OECD (2001) and Bafor and Igbinuwen (2009) was used in a 24 hours single, 14 days single, and 14 days daily doses toxicity study of the aqueous extract of the bi-herbal formulation of *Garcinia kola* and *Carica papaya* roots (BH ("Makanne")). The experimental group consist of extract-treated and control groups of 5 animals each. The extract groups were given 2 g/kg, and control groups received 10 ml/kg of distilled water orally using orogastric tube fitted to a 1 ml syringe. In the single-dose (24 hr) treatment group, the animals were given 2 g/kg BH extract, and the control group (DW) received 10 ml/kg of distilled water on the first day (D0) and after 24 hr (D1) the weight and temperature were taken before the animals were anaesthetized. In single dose (14 Days) treatment, the extract group received 2 g/kg of BH extract, and the control group received

10 ml/kg of distilled water (DW) on the first day (D0) (Committee, 2011). The weight and temperature were taken on D0, D7 and D13 before being anaesthetized on last day D14. However, in Daily Dose (14 Days) treatment, the extract group received 2 g/kg BH extract and the control (DW) group received 10 ml/kg distilled water daily for 14 days. The mice body weight and temperature were taken daily before administration and on the last day before anaesthetized. The mice were observed daily for any sign of sickness or changes in behavior or death. The animals were anesthetized with cotton wool soaked in chloroform in a closed system (Bradbury, 1977). They were dissected longitudinally over the abdomen. Blood (0.4-0.6 ml) was collected through cardiac puncture and from the abdominal aorta into EDTA anticoagulant blood sample bottle, the blood was properly mixed to avoid forming a blood clot. Blood cell analysis was done using Mythic 18 auto-analyzer, 3 Parts differential (Germany). The kidney and liver were located and excise, adhering tissues and fat were removed. They were examined macroscopically and weighed and were fixed in 10 % formalin for histological processing. The organs were dehydrated in ascending grades of ethanol before embedding in paraffin wax, they were sectioned and stained with hematoxylin and eosin. The stained slides were viewed using the Olympus cameral microscope and photomicrographs were taken with x40 objective.

Data Analyses

The results obtained were subjected to relevant statistical analyses. Data were presented as percentage of control in mean ± S.E.M (standard error of mean). Comparisons were made using one-way repeated measures ANOVA with Dunnett's correction for multiple comparison or student's t-test where appropriate. $P \leq 0.05$ was used to indicate statistical significance. Graph pad prism 9.00 (California, USA) and Microsoft office excel were used.

RESULTS

Acute Toxicity

Mice Weight and Temperature

There was no significant increase in the body weight and temperature of 2 g/kg aqueous bi-herbal root extract of *Garcinia kola* and *Carica papaya* (BH) and the control (DW) in each of the groups 24 hr, 14 days single dose and 14 days daily dose Figure 1and Figure 2.

Haematology (24 hr) Treatment

The blood cell count showed significant increase ($P < 0.05$) in white blood cells, lymphocytes, mean corpuscular haemoglobin concentration, red blood cells, haemoglobin and platelets count but significant decrease in monocytes and granulocytes in 2 g/kg BH extract group compared to control group ($P < 0.05$) shown in Table 1.

Haematology Single Dose (14 Days) Treatment

There was a significant increase in platelet count and a significant decrease in mean corpuscular haemoglobin concentration (MCHC) in BH extract group compared to the control group. There was no significant change in all other blood cell parameters (Table 2).

Haematology Daily Dose (14 Days) Treatment

Granulocytes, mean corpuscular volume and platelet count were significantly increased in 2 g/kg BH extract group compared to the control group. All other parameters showed statistically insignificant changes when compared with control (Table 3).

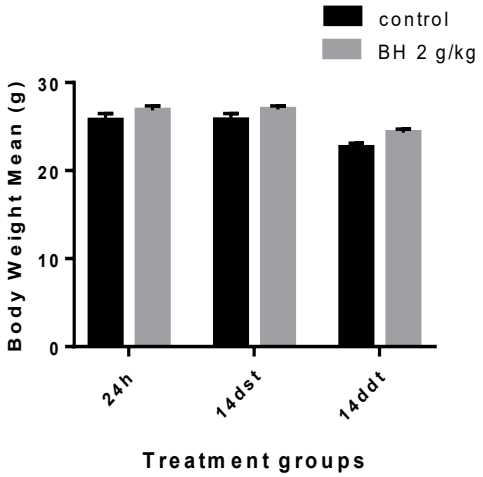

Figure 1: Effect of aqueous bi-herbal root extract of *Garcinia kola* and *Carica papaya* (BH) on the body weight of female mice (n = 5).

Key: 24h--- 24 hour group, 14dst--- 14 days single dose group, 14ddt--- 14 days daily dose group.

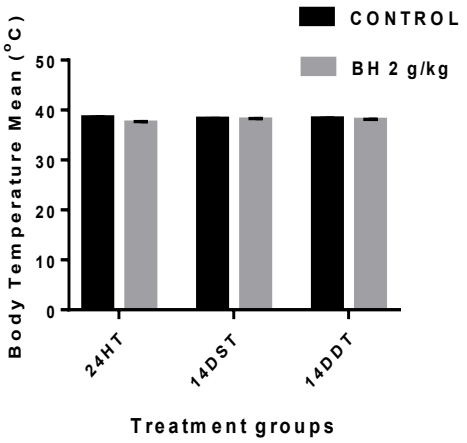

Figure 2: Effect of aqueous bi-herbal root extract of *Garcinia kola* and *Carica papaya* (BH) extract on the body temperature of female mice (n = 5). Key: 24HT--- 24 hour group, 14DST--- 14 days single dose group, 14DDT--- 14 days daily dose group.

Table 1: Effect of aqueous bi-herbal root extract of *Garcinia kola* and *Carica papaya* (BH) extract on haematological parameters in 24 hr treatment group

Haematological Parameters	Groups	
	Control	**BH (2 g/kg)**
WBC $x10^3mm^{-3}$	3.38 ± 0.53	5.18 ± 0.39*
LYM $x10^3mm^{-3}$	2.26 ± 0.23	4.62± 0.39*
MO $x\ 10^3mm^{-3}$	0.78 ± 0.06	0.22 ± 0.05#
GR $x\ 10^3mm^{-3}$	1.02 ± 0.24	0.34 ± 0.04#
RBC $x10^3mm^{-3}$	6.68±0.57	8.17±0.16*
HGB g/dl	10.64 ± 1.02	13.96 ± 0.26*
MCV fl	52.12 ± 0.63	52.34 ± 0.39
MCH pg	13.82 ± 1.73	17.02 ± 0.07
MCHC g/dl	30.14 ± 0.43	32.54 ± 0.19*
PLT $x\ 10^3mm^{-3}$	424.44 ± 40.19	747.41 ± 13.32*

WBC = white blood cell; **LYM** = lymphocytes; **MO** = monocytes; **GR** = granulocytes; **RBC** = red blood cell count; **HGB =** haemoglobin concentration; **MCV** = mean corpuscular volume; **MCH** = mean corpuscular haemoglobin; **MCHC** = mean

corpuscular haemoglobin concentration; **PLT** = platelet count; * significant increase; # significant decrease relative to the control; $P < 0.05$; n = 5.

Table 2: Effect of aqueous bi-herbal root extract of *Garcinia kola* and *Carica papaya* (BH) on haematological parameters in 14 days single dose treatment group

Haematological Parameters	Groups	
	Control	**CA (2 g/kg)**
WBC $x10^3mm^{-3}$	3.88±0.53	5.38 ±0.85
LYM $x10^3mm^{-3}$	2.26±0.23	3.38±0.53
MO $x\ 10^3mm^{-3}$	0.78 ±0.06	0.92±0.07
R $x\ 10^3mm^{-3}$	1.02 ±0.24	1.24±0.32
RBC $x10^3mm^{-3}$	6.69±0.58	8.72±1.17
HGB g/dl	10.64±1.02	11.78±0.71
MCV fl	52.12±0.63	50.94±0.89
MCH pg	13.82±1.73	14.08±1.41
MCHC g/dl	30.14 ±0.43	27.82±3.03#
PLT $x\ 10^3mm^{-3}$	424.40±47.19	464.8±58.70*

WBC = white blood cell; **LYM** = lymphocytes; **MO** = monocytes; **GR** = granulocytes; **RBC** = red blood cell count; **HGB =** haemoglobin concentration; **MCV** = mean corpuscular volume; **MCH** = mean corpuscular haemoglobin; **MCHC** = mean corpuscular haemoglobin concentration; **PLT** = platelet count; * significant increase; # significant decrease relative to the control; $P < 0.05$; n = 5.

Table 3: Effect of aqueous bi-herbal root extract of *Garcinia kola* and *Carica papaya* (BH) on haematological parameters in 14 days daily dose treatment group

Haematological Parameters	Groups	
	Control	**BH (2 g/kg)**
WBC $x10^3mm^{-3}$	3.06 ± 0.70	4.64±0.28
LYM $x10^3mm^{-3}$	2.58 ±0.68	3.54±0.26
MO $x\ 10^3mm^{-3}$	0.16 ±0.05	0.34±0.10
GR $x\ 10^3mm^{-3}$	0.38 ±0.08	0.80±0.36*
RBC $x10^3mm^{-3}$	8.07±0.51	9.16±0.17

HGB g/dl	14.40±1.00	16.20±0.50
MCV fl	54.72±1.64	54.84±0.35*
MCH pg	17.80±0.16	17.62±0.30
MCHC g/dl	32.58±1.01	32.16±0.57
PLT x $10^3 mm^{-3}$	409.8±9.26	856.4±13.80*

WBC = white blood cell; **LYM** = lymphocytes); **MO** = monocytes; **GR** = granulocytes; **RBC** = red blood cell count; **HGB =** haemoglobin concentration; **MCV** = mean corpuscular volume; **MCH** = mean corpuscular haemoglobin; **MCHC** = mean corpuscular haemoglobin concentration; **PLT** = platelet count; * significant increase; # significant decrease relative to the control; $P < 0.05$; $n = 5$.

Relative Vital Organs Weight (24 hr)

There was no significant difference between the relative weight of kidney and liver in aqueous bi-herbal root extract of *Garcinia kola* and *Carica papaya* **(**BH) and the control groups (Figure3 and Figure 4).

Relative Vital Organs Weight Single Dose (14 Days)

The relative weight of kidney and liver in BH extract 2 g/kg and the control groups were not significantly different (Figure 5 and Figure 6).

Relative Vital Organs Weight Daily Dose (14 Days)

The relative weights of kidney and liver in BH extract 2g/kg group were not significantly different from those in the control group (Figure 7 and Figure 8)

Vital Organs histopathology (24 hr)

Photomicrographs revealed normal structural cell architecture. Liver showed normal central vein, normal hepatocytes with conspicuous nuclei and activated sinusoidal kupffer cells compared with the control (Plate 1A and 1B); Kidney revealed normal glomerulus, interstitial space and normal tubules (Plate 2C and 2D).

Vital Organs histopathology Single Dose (14 Days)

Photomacrograph of liver reveals active vascular congestion, normal hepatocytes with conspicuous nucleoli and periportal mobilisation of lymphocytes and kupffer cells (Plate 3B) compared with the control (Plate 3A); kidney reveals normal glomerulus, active interstitial congestion and normal tubules (Plate 4D) compared with the control (Plate 4C).

Vital Organs histopathology Daily Dose (14 Days)

Photomicrographs Liver showed normal central vein, normal hepatocytes with conspicuous nucleoli and florid activated sinusoidal kupffer cells compared to control (Plate 5A and 5B); kidney revealed normal glomeruli, interstitial space and normal tubules compared to control (Plate 6C and 6D).

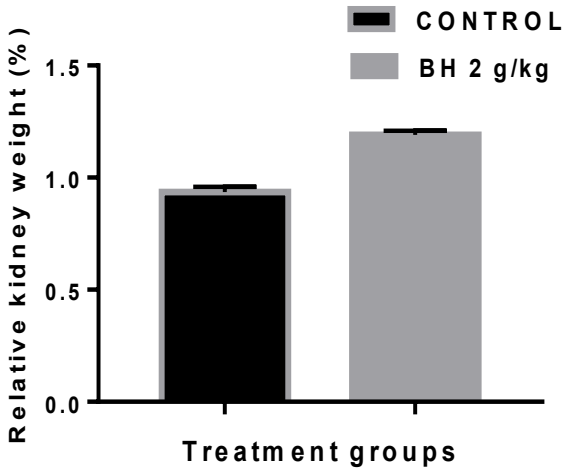

Figure 3: Effect of aqueous bi-herbal root extract of *Garcinia kola* and *Carica papaya* (BH) on relative kidney weight in 24 hr single dose treatment group of female mice (n = 5).

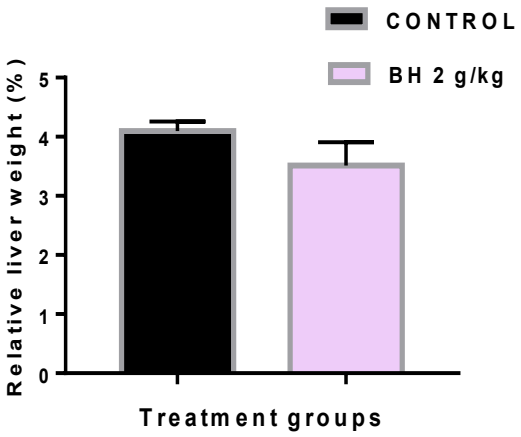

Figure 4: Effect of aqueous bi-herbal root extract of *Garcinia kola* and *Carica papaya* (BH) on relative liver weight in 24 hr single dose treatment group of female mice (n = 5).

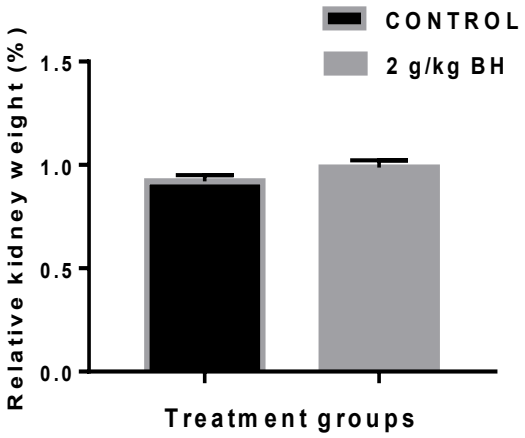

Figure 5: Effect of aqueous bi-herbal root extract of *Garcinia kola* and *Carica papaya* (BH) on relative kidney organ weight in 14 days single dose treatment group of female mice (n = 5).

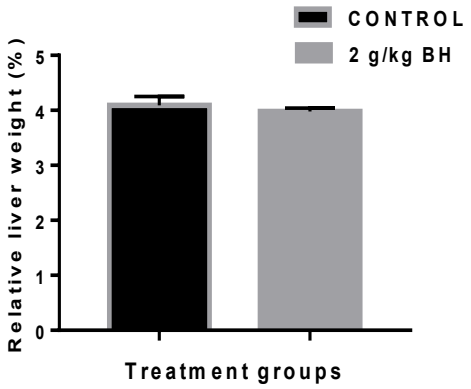

Figure 6: Effect of aqueous bi-herbal root extract of *Garcinia kola* and *Carica papaya* (BH) on relative liver organ weight in 14 days single dose treatment group of female mice (n = 5).

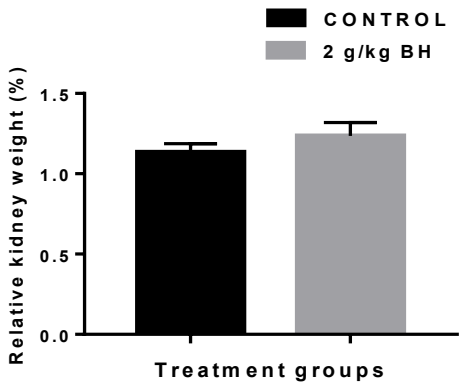

Figure 7: Effect of aqueous bi-herbal root extract of *Garcinia kola* and *Carica papaya* (BH) on relative kidney weight of female mice in 14 days daily dose treatment group (n = 5).

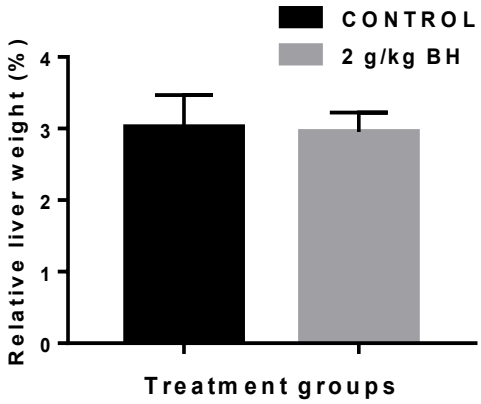

Figure 8: Effect of aqueous bi-herbal root extract of *Garcinia kola* and *Carica papaya* (BH) on relative liver weight of female mice in 14 days daily dose treatment group (n = 5).

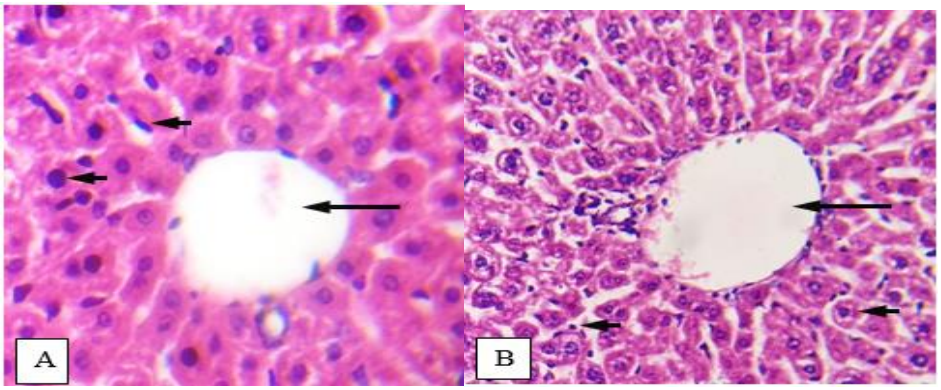

Plate 1: Effect of aqueous bi-herbal root extract of *Garcinia kola* and *Carica papaya* (BH) on the histopathological structure of the liver in 24 hr treatment group of female mice (H & E stain, X40 objective).

(A) ControL Liver histology showed central vein (long arrow), hepatocytes with centrally placed nucleus (short arrow) and sinusoids.

(B) BH Extract Liver histology revealed normal central vein (long arrow), normal hepatocytes with conspicuous nuclei and activated sinusoidal kupffer cells (short arrow).

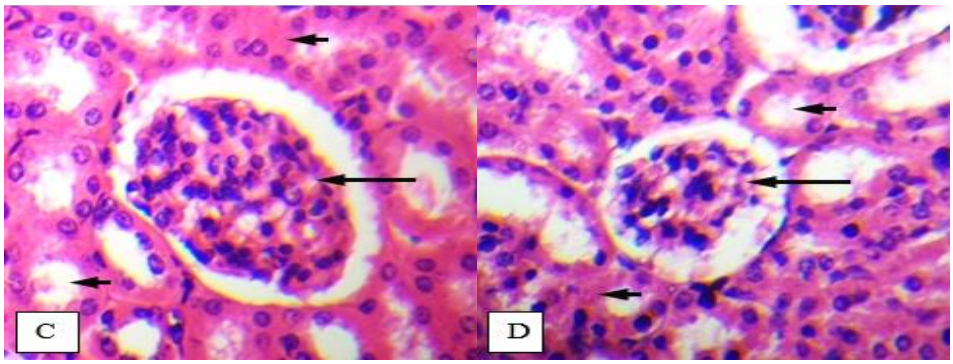

Plate 2: Effect of aqueous bi-herbal root extract of *Garcinia kola* and *Carica papaya* (BH) on the histopathological structure of the kidney in 24 hr treatment group of female mice (H & E stain, X40 objective).

(C) Control Kidney reveal normal glomerulus (long arrow), interstitial space and normal tubules (short arrow).

(D) BH Extract Kidney reveal normal glomerulus (long arrow), interstitial space and normal tubules (short arrow).

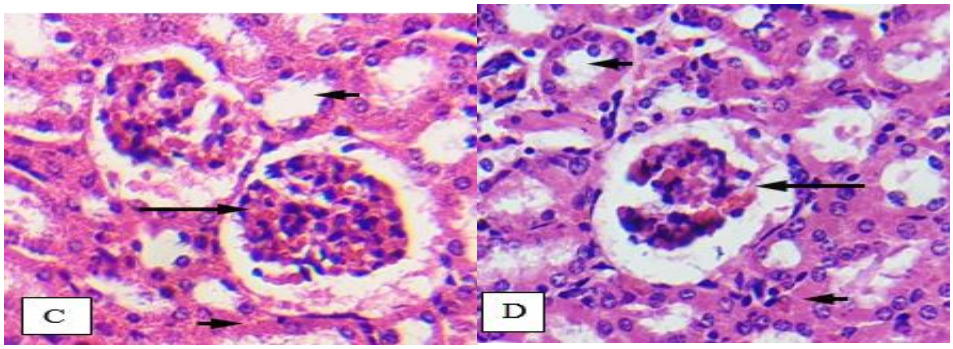

Plate 3: Effect of aqueous bi-herbal root extract of *Garcinia kola* and *Carica papaya* (BH on the histopathological structure of the kidney in 14 days single dose treatment group of female mice (H & E stain, X40 objective).

(C) Control Kidney reveals normal glomeruli (long arrow), interstitial space and normal tubules (short arrow).

(D) BH Extract Kidney reveals normal glomerulus (long arrow), active interstitial congestion and normal tubules (short arrow).

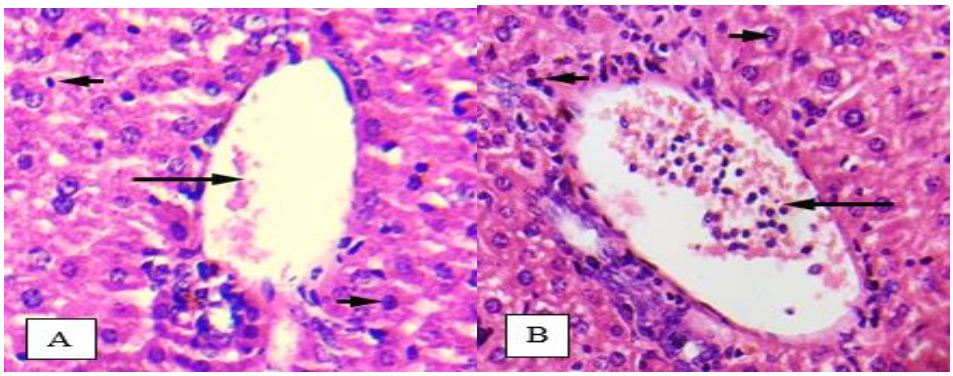

Plate 4: Effect of aqueous bi-herbal root extract of *Garcinia kola* and *Carica papaya* (BH on the histopathological structure of the liver in 14 days single dose treatment group of female mice (H & E stain, X40 objective).

(A) Control Liver histology showed normal central vein (long arrow), normal hepatocytes and sinusoids (short arrow).

(B) BH Extract Liver histology revealed active vascular congestion (long arrow), normal hepatocytes with conspicuous nucleoli and periportal mobilisation of lymphocytes and kupffer cells (short arrow).

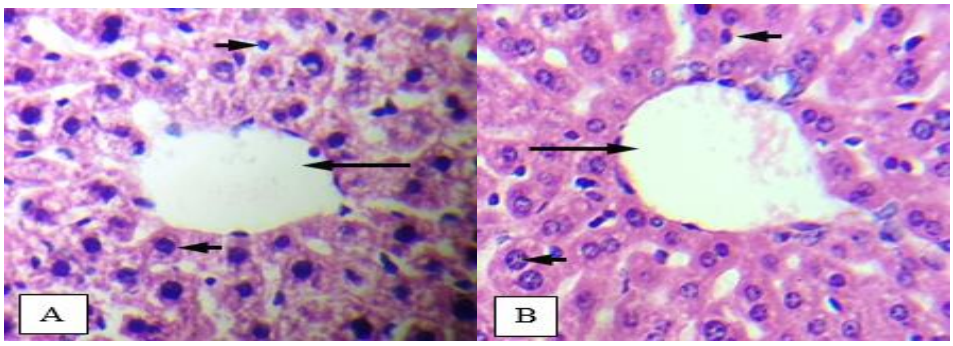

Plate 5: Effect of aqueous bi-herbal root extract of *Garcinia kola* and *Carica papaya* (BH) on the histopathological structure of the liver in 14 days daily dose treatment group of female mice (H & E stain, X40 objective).

(A) Control Liver histology shows normal central vein (long arrow), normal hepatocytes with centrally placed nucleus and sinusoids (short arrow).

B) BH Extract Liver histology shows normal central vein (long arrow), normal hepatocytes with conspicuous nucleoli and florid activated sinusoidal kupffer cells (short arrow).

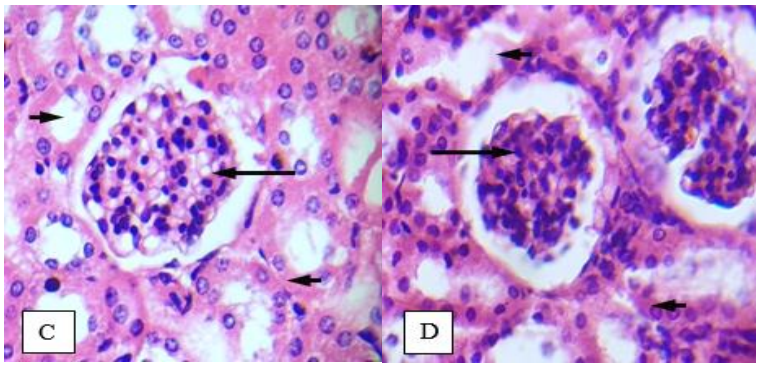

Plate 6: Effect of aqueous bi-herbal root extract of *Garcinia kola* and *Carica papaya* (BH) on the histopathological structure of the kidney in 14 days daily dose treatment group of female mice (H & E stain, X40 objective).

(C) Control Kidney reveals normal glomerulus (long arrow), interstitial space and normal tubules (short arrow).

(D) BH Extract Kidney reveals normal glomeruli (long arrow), interstitial space and normal tubules (short arrow).

DISCUSSION

Systematic toxicity investigations are crucial for determining safe consumption levels in humans, ensuring the safe use of plant-derived products. Prior to initiating clinical trials to assess the efficacy of herbal products, it is standard practice to conduct preliminary acute and chronic toxicity tests in animal models. This foundational phase is crucial for determining optimal dosages and the appropriate duration of administration, establishing a sound basis for subsequent human trials (Sireeratawong et al., 2016). The acute oral toxicity test is pivotal for evaluating immediate adverse effects following a significant single oral dose of a substance within a 24-hour, 14-days and daily dose for 14-days period. In our study, a dose of 2 g/kg of **the biherbal formulation** was administered to assess its safety profile. This dose was selected based on previous studies that utilized a 2 g/kg dosage for Hippocratic screening, a technique used to identify notable pharmacological activities in medicinal plants which showed no toxic or lethal results. This is in line with the work of Santana *et al.* (2019) and Hasan *et al.* (2018). A critical parameter for identifying potential toxicity is monitoring changes in general behavior and body weight. The literature suggests that a loss exceeding 10% of initial body weight in test animals could indicate adverse side effects and may impact survival. However, with no significant difference in mice weight,

the biherbal extract resulted in neither mortality nor significant changes in body weight compared to a control group. The results indicated that the extract at a dose of 2 g/kg had no significant difference in the body temperature of the treated animals across single doses of 24 hrs and 14 days and daily doses of 14 days when compared with the control. The report of Norahmad *et al.* (2019) align with this present study. Hematology analyses are critical tools for detecting potential tissue damage or physiological stress, providing insights into the cellular health of internal organs. Given the role of the circulatory system in distributing nutrients and foreign substances, blood serves as a sensitive indicator of both physiological and pathological conditions. Toxic substances can compromise essential blood components, such as red and white blood cells, platelets, and hemoglobin. Abdel-halim et al. (2021) and Ostermann and Joannidis (2016) agreed with the findings of this study. In our study we observed some significant deviations in blood parameters platelet, in all treated groups was significantly increased and 24 hr single dose elicited a significant increase in white blood cell count, lymphocyte, red blood cell count, hemoglobin, platelet and mean corpuscle hemoglobin concentration when compared with the control ($p<0.05$). Variations in internal organ weights are acknowledged as sensitive indicators for evaluating the effects of drug exposure on organ health. Such assessments are essential in toxicological studies, where organ weights of treated and untreated animals are systematically compared. The report of Estella *et al.* (2020) and Diferelanko (2016) concurred with our work. In our investigation, gross pathological examinations revealed no significant abnormalities in the internal organs of the **biherbal formualed** extract-treated groups, aligning with findings from the control groups. Following the OECD Test Guideline 452, the data obtained from this study substantiates the non-toxic profile of **the biherbal formualed** extract-treated. Furthermore, detailed histological examinations of the liver and kidneys, revealed no tissue damage. Importantly, no deaths were recorded in this study, which aligns with existing literature citing the LD_{50} for **biherbal formulation** extract to be well above 5000 mg/kg following a single oral dose of the substance within a 24-hour, 14-days and daily dose for 14-days period. Our findings showed no indications of toxicity or histopathological abnormalities across all treatment groups, particularly in the liver and kidney as reported by Nghonguyi *et al.* (2016).

CONCLUSION

In conclusion, the current study provides strong evidence of the safety of **the biherbal formulation** on the acute toxicity tests involving a single oral dose of 2 g/kg for 24 hr and 14 days and daily dose of 14 days revealed no adverse effects on the body weight, temperature, hematology, organs weight (liver and kidney) and the histopathological evaluations on the organs. Hence, further studies is required for chronic toxicity and therapeutic investigations.

REFERENCES

Abdel-Halim, S., Ibrahim, M., Abdel Mohsen, M., Abou-Setta, L., Sleem, A. and El-Missiry, M. (2021). The influence of the extraction method on polyphenols, flavonoids composition and anti-hyperlipidemic properties of papaya leaves (*Carica papaya* Linn.). *Bull. Natl. Res. Cent.* 45: 85.

Bafor, E. E and Igbinuwen, O. (2009). Acute toxicity studies of the leaf extract of *Ficus exasperata* on haematological parameters, body weight and body temperature. *Journal of Ethnopharmacology,* 123:302 – 307.

Balekundri, A. and Mannur, V. (2020). Quality control of the traditional herbs and herbal products: A review. *Futur. J. Pharm. Sci.* 6:67.

Bradbury, P. (1977). In: Hewer's Textbook of Histology for Medical Students (9th Ed.) EL ELBS, OCLC 6565 Kilgour Place, Dublin OH USA, pp 431- 450.

Committee (2011). Guide for the care and use of laboratory animals. In: *guide for care and use of laboratory animals*, Eight Edition, p. 118.

Diferelanko, M.J. (2017). *The Toxicologist's Pocket Handbook*; Taylor & Francis: Abingdon, UK.

Estella, O.U., Ogoamaka, O.P. and Emmanuel, E.F. (2020). Evaluation of the oxytocic and haematogical effects of leaves of *Carica papaya* Linn (Caricaceae). *World J. Adv. Res. Rev.* 6: 212–226.

Gadhwal, A.K., Ankit, B.S., Chahar, C., Tantia, P., Sirohi, P. and Agrawal, R.P. (2016). Effect of *Carica papaya* Leaf Extract Capsule on Platelet Count in Patients of Dengue Fever with Thrombocytopenia. *J. Assoc. Physicians India.* 64: 22–26.

Hasan, K.M.M., Tamanna, N. and Haque, M.A. (2018). Biochemical and histopathological profiling of Wistar rat treated with Brassica napus as a supplementary feed. *Food Sci. Hum. Wellness.7*: 77–82.

Jităreanu, A., Trifan, A., Vieriu, M., Caba, I.-C., Mârţu, I. and Agoroaei, L. (2023). Current Trends in Toxicity Assessment of Herbal Medicines: A Narrative Review. *Processes.* 11: 83.

Lim, X.Y., Chan, J.S.W., Japri, N., Lee, J.C. and Tan, T.Y.C. (2021). *Carica papaya* L. Leaf: A Systematic Scoping Review on Biological Safety and Herb-Drug Interactions. *Evid. Based Complement. Alternat. Med.*5511221.

Longdet, I. and Adoga, E. (2017). Effect of methanolic leaf extract of *Carica papaya* on plasmodium berghei infection in albino mice. *Eur. J. Med. Plants*,, 20: 1–7.

Nair, A.B. and Jacob, S. (2016). A simple practice guide for dose conversion between animals and human. *J. Basic. Clin. Pharm.* 7: 27–31.

Nariya, A. and Jhala, D. (2017). Pharmacognostic study of *Carica papaya* leaf extract as inhibitors of reactive oxygen species. *Int. Res. J. Pharm.* 8*:* 13–17.

Nghonjuyi, N.W., Tiambo, C.K., Taïwe, G.S., Toukala, J.P., Lisita, F., Juliano, R.S. and Kimbi, H.K. (2016). Acute and sub-chronic toxicity studies of three plants used in Cameroonian ethnoveterinary medicine: *Aloe vera* (L.) Burm. f. (Xanthorrhoeaceae) leaves, *Carica papaya* L. (Caricaceae) seeds or leaves, and *Mimosa pudica* L. (Fabaceae) leaves in Kabir chicks. *J. Ethnopharmacol. 178*, 40–49.

Norahmad, N.A., Mohd Abd Razak, M.R., Mohmad Misnan, N., Md Jelas, N.H., Sastu, U.R., Muhammad, A., Ho, T.C.D., Jusoh, B., Zolkifli, N.A.and Thayan, R. (2019). Effect of freeze-dried *Carica papaya* leaf juice on inflammatory cytokines production during dengue virus infection in AG129 mice. *BMC Complement. Altern. Med.* 19: 44.

Organization of Economic Co-operation and Development (2001). *The OECD guideline for testing of chemicals: 420 acute oral toxicity-fixed. Doseprocedure*. Paris, France.

Ostermann, M. and Joannidis, M. (2016). Acute kidney injury 2016: Diagnosis and diagnostic workup. *Crit. Care*, 20: 299.

Phromnoi, K., Yodkeeree, S., Pintha, K., Mapoung, S., Suttajit, M., Saenjum, C. and Dejkriengkraikul, P. (2022). Anti-Osteoporosis Effect of *Perilla frutescens* Leaf Hexane Fraction through Regulating Osteoclast and Osteoblast Differentiation. *Molecules.* 27*:* 824.

Rahmat, L.T. and Damon, L.E. (2018). The Use of Natural Health Products Especially Papaya Leaf Extract and Dandelion Root Extract in Previously Untreated Chronic Myelomonocytic Leukemia. *Case. Rep. Hematol.* 7267920.

Santana, L.F., Inada, A.C., Espirito Santo, B.L.S.d., Filiú, W.F.O., Pott, A., Alves, F.M., Guimarães, R.d.C.A., Freitas, K.d.C. and Hiane, P.A. (2019). Nutraceutical Potential of *Carica papaya* in Metabolic Syndrome. *Nutrients,* 11: 1608.

Sathyapalan, D.T., Padmanabhan, A., Moni, M., P-Prabhu, B., Prasanna, P., Balachandran, S., Trikkur, S.P., Jose, S., Edathadathil, F. and Anilkumar, J.O. (2020). Efficacy & safety of *Carica papaya* leaf extract (CPLE) in severe thrombocytopenia (≤30,000/μL) in adult dengue-Results of a pilot study. *PLoS ONE*.15: e0228699.

Sheneni, V., Shaibu, I., Okpe, J. and Omada, A. (2018). In-vivo biological effect of *Carica papaya* leaf extracts on P-407 induced hyperlipidemic Wistar rats. *MOJ Food Process Technol.* 6:409–412.

Sireeratawong, S., Jaijoy, K., Khonsung, P., Lertprasertsuk, N. and Ingkaninan, K. (2016). Acute and chronic toxicities of *Bacopa monnieri* extract in Sprague-Dawley rats. *BMC Complement. Altern. Med.* 16:249.

Sobia, K., Javaid, M., Ahmad, M.S., Rehmatullah, Q., Hina, G., Iram, B., Pervaiz, A., Farhana, B., Nyla, J. and Gulfraz, M. (2016). Assessments of phytochemicals and hypoglycemic activity of leaves extracts of *Carica papaya* in diabetic mice. *Int. J. Pharm. Sci. Rev. Res.*7:3658.

Subramanian, K., Sankaramourthy, D. and Gunasekaran, M. (2018) Chapter 18-Toxicity Studies Related to Medicinal Plants. In *Natural Products and Drug Discovery*; Mandal, S.C., Mandal, V., Konishi, T., Eds.; Elsevier: Amsterdam, The Netherlands, pp. 491–505.

Teh, B.P., Ahmad, N.B., Mohamad, S.B. Tan, T.Y.C., Mohd Abd Razak, M.R.B., Afzan, A.B. and Syed Mohamed, A.F.B. (**2022)** *Carica papaya* Leaf Juice for Dengue: A Scoping Review. *Nutrients* 14: 1584.

Teng, W.-C., Chan, W., Suwanarusk, R., Ong, A., Ho, H.-K., Russell, B., Rénia, L. and Koh, H.-L. (2019). In vitro antimalarial evaluations and cytotoxicity investigations of *Carica papaya* leaves and carpaine. *Nat. Prod. Commun.* 14: 1934578X1901400110.

World Health Organization (2019). *WHO Global Report on Traditional and Complementary Medicine 2019*; World Health Organization: Geneva, Switzerland.