African Journal of
Biochemistry and Molecular Biology Research

ISSN : 1595-7926

Index: Harvard, Boston, Sydney University, Dimensions, Lens, ResearchGet Scilit, Semantic, Google Scholar, Base etc

https://doi.org/10.58578/AJBMBR.v3i1.8299

Neurotoxic Effect of Cassava Cyanide on the Motor Activity and Cytoarchitecture of the Cerebellar Cortex of Albino Rats

Isaac John Umaru[1], Tyem Lawal Danjuma[2], Katchim Evelyn Shadrach[3], Julius Ishaya Salman[4], Jibaniya, Grace Mchibuma[5], Kerenhappuch Isaac Umaru[6]

[1,3,4,5,6]Federal University Wukari. Taraba State, Nigeria

[2]College of Health Sciences. University of Jos, Nigeria

Email: umaruisaac@gmail.com

Article Info:

Submitted:	Revised:	Accepted:	Published:
Oct 20, 2025	Nov 25, 2025	Dec 8, 2025	Dec 13, 2025

Abstract

Cassava (*Manihot esculenta* Crantz), a widely consumed staple in tropical regions, contains cyanogenic glycosides that release hydrogen cyanide (HCN) upon hydrolysis. Chronic exposure to cassava-derived cyanide has been implicated in neurodegenerative disorders, particularly affecting motor coordination and cerebellar function. This study investigates the neurotoxic effects of cassava cyanide on motor activity and cerebellar cytoarchitecture in albino Wistar rats. Thirty adult male rats were divided into three groups: control, low-dose cyanide (10 mg/kg), and high-dose cyanide (20 mg/kg), administered orally for 15 days. Motor performance was assessed using rotarod and open field tests, while cerebellar tissues were examined histologically using hematoxylin and eosin staining. Results revealed a dose-dependent decline in motor coordination and locomotor activity, with significant reductions in rotarod latency and open field distance in cyanide-treated groups compared to controls ($p < 0.05$). Histological analysis showed progressive Purkinje cell degeneration, vacuolation, and disrupted laminar architecture in the cerebellar cortex, particularly in the high-dose group.

AJBMBR Journal is licensed under a Creative Commons Attribution-NonCommercial-ShareAlike 4.0 International License

These findings suggest that cassava cyanide exerts neurotoxic effects on cerebellar neurons, impairing motor function through structural damage. The study underscores the importance of safe cassava processing and dietary interventions to mitigate cyanide-induced neurotoxicity in vulnerable populations.

Keywords: Cassava-Derived Cyanide; Cyanogenic Glycosides; Cerebellar Cortex; Purkinje Cell Degeneration; Motor Coordination

INTRODUCTION

Cassava (*Manihot esculenta Crantz*) is a vital food crop cultivated extensively across tropical and subtropical regions, particularly in sub-Saharan Africa, Southeast Asia, and Latin America. Its resilience to drought and poor soils, coupled with its high carbohydrate content, makes it a reliable source of calories for millions of people (Rivadeneyra-Domínguez & Rodríguez-Landa, 2020). However, despite its nutritional importance, cassava poses significant health risks due to the presence of cyanogenic glycosides—primarily linamarin and lotaustralin. These compounds, when enzymatically hydrolyzed during processing or digestion, release hydrogen cyanide (HCN), a potent and potentially lethal neurotoxin (Jørgensen et al., 2011; Manalo, Ong, & Medina, 2025).

The toxicity of cassava is influenced by several factors, including the variety of the plant (bitter vs. sweet), processing methods, and dietary context. Bitter cassava varieties contain higher concentrations of cyanogenic glycosides and require thorough processing—such as soaking, fermenting, and drying—to reduce cyanide levels to safe thresholds (Ndubuisi & Chidiebere, 2018). Inadequate processing, often due to food insecurity or lack of awareness, can lead to chronic cyanide exposure, particularly in communities where cassava is a dietary staple and protein intake is insufficient to support detoxification pathways (Adamolekun, 2011).

Chronic exposure to cassava-derived cyanide has been epidemiologically linked to a spectrum of neurodegenerative disorders. Among the most notable are konzo—a sudden-onset, non-progressive spastic paraparesis—and tropical ataxic neuropathy (TAN), characterized by sensory deficits, ataxia, and optic neuropathy (Nzwalo & Cliff, 2011; Garg, 2024). These conditions are prevalent in regions where cassava consumption is high and

dietary sulfur amino acids, essential for cyanide detoxification via the rhodanese pathway, are deficient (Kimani, 2013).

The cerebellum, a brain region integral to motor coordination, balance, and fine motor control, is particularly susceptible to cyanide-induced neurotoxicity. Cyanide disrupts cellular respiration by inhibiting cytochrome c oxidase in the mitochondrial electron transport chain, leading to energy failure, oxidative stress, and neuronal death (Ayuba, 2015; Kimani, 2015). Purkinje cells, the principal neurons of the cerebellar cortex, are highly metabolically active and vulnerable to such insults, making them key targets in cyanide-mediated neurodegeneration (Aliyu, 2015).

Despite the clinical relevance of cassava-related neurotoxicity, experimental studies elucidating the specific effects of cyanide on cerebellar structure and motor function remain limited. Animal models, particularly albino rats, offer a controlled platform to investigate the neuropathological consequences of cyanide exposure and to simulate the dietary conditions observed in affected human populations (Abdulbasit, 2014).

This study aims to evaluate the neurotoxic effects of cassava cyanide on the motor activity and cerebellar cytoarchitecture of albino rats. By integrating behavioral assays and histological analysis, the research seeks to provide mechanistic insights into how cyanide disrupts cerebellar function and contributes to motor deficits, thereby informing public health strategies and dietary interventions in cassava-dependent regions.

The cerebellum is a highly organized brain structure responsible for the regulation of motor coordination, balance, and fine-tuned voluntary movements. It plays a pivotal role in integrating sensory input with motor commands to ensure smooth and precise execution of tasks such as walking, posture control, and reflex modulation (Rivadeneyra-Domínguez & Rodríguez-Landa, 2020). Due to its high metabolic activity and dense neuronal architecture, particularly the Purkinje cells the cerebellum is especially vulnerable to neurotoxic insults, including those induced by environmental and dietary toxins.

One such toxin is hydrogen cyanide (HCN), a byproduct of cyanogenic glycosides found in cassava (*Manihot esculenta* Crantz). These glycosides, primarily linamarin and lotaustralin, are enzymatically hydrolyzed during cassava processing or digestion, releasing cyanide into the body (Manalo, Ong, & Medina, 2025). Inadequate detoxification, especially in individuals with protein-deficient diets, can lead to chronic cyanide exposure and

accumulation, resulting in oxidative stress, mitochondrial dysfunction, and neuronal damage (Kimani et al., 2013).

Cyanide exerts its neurotoxic effects by inhibiting cytochrome c oxidase in the mitochondrial electron transport chain, leading to impaired ATP production and increased reactive oxygen species (ROS). This cascade of events contributes to neuronal apoptosis, gliosis, and structural disintegration of neural tissues, particularly in the cerebellar and cortical regions (Ayuba, 2015). Additionally, cyanide exposure has been linked to protein carbamoylation—a post-translational modification that disrupts protein function and contributes to neurodegeneration (Kimani et al., 2013).

Epidemiological studies have associated chronic cassava consumption with neurological disorders such as konzo and tropical ataxic neuropathy (TAN), both characterized by motor deficits and cerebellar involvement (Enefa, Paul, & David, 2020). However, despite these clinical observations, experimental data on the specific effects of cassava-derived cyanide on cerebellar cytoarchitecture and motor behavior remain limited. Animal models, particularly albino rats, offer a valuable platform to investigate these effects under controlled conditions, simulating the dietary and environmental factors present in cassava-dependent populations.

This study aims to bridge the gap in experimental knowledge by evaluating the neurotoxic impact of cassava cyanide on motor activity and cerebellar histology in albino rats. Through behavioral assessments and histopathological analysis, the research seeks to elucidate the mechanisms by which cyanide disrupts cerebellar function and contributes to motor impairments, thereby informing public health strategies and dietary recommendations in regions reliant on cassava as a staple food.

MATERIALS AND METHODS

Experimental Animals

Thirty adult male albino Wistar rats (180–220 g) were procured from a certified animal facility and acclimatized for one week under standard laboratory conditions: 12-hour light/dark cycle, ambient temperature of 25 ± 2°C, and ad libitum access to food and water (Rivadeneyra-Domínguez & Rodríguez-Landa, 2020). All procedures were approved

by the institutional animal ethics committee and adhered to international guidelines for the care and use of laboratory animals.

Experimental Design

Rats were randomly divided into six groups (n = 5 per group):

Group A (Control): Received standard diet and distilled water.

Administered cassava-derived cyanide orally for 15 days.

Group B (100 mg cyanide): Administered 100 mg/kg body weight

Group C (200 mg cyanide): Administered 200 mg/kg body weight.

Group D (300 mg cyanide): Administered 300 mg/kg body weight.

Group E (400 mg cyanide): Administered 400 mg/kg body weight.

Group F (500 mg cyanide): Administered 500 mg/kg body weight.

Cassava cyanide extract was prepared from bitter cassava tubers using standard hydrolysis and filtration methods (Manalo, Ong, & Medina, 2025). Doses were selected based on prior studies demonstrating graded neurotoxicity in rodents (Ayuba, 2015; Kimani et al., 2013).

Motor Activity Assessment

Motor coordination was assessed using: Rotarod Test: Rats were placed on a rotating rod (20 rpm), and latency to fall was recorded across three trials.

Open Field Test: Rats were placed in a square arena, and total distance moved was recorded over 5 minutes using a digital tracking system (Enefa, Paul, & David, 2020). Assessments were conducted on days 0, 7, and 15.

Histological Analysis

At the end of the experiment, rats were euthanized under mild anesthesia. Cerebellar tissues were harvested, fixed in 10% formol-saline, and processed using paraffin embedding. Sections (5 μm) were stained with hematoxylin and eosin (H&E) and examined under light microscopy for cytoarchitectural changes, focusing on Purkinje cells, granular layers, and signs of neurodegeneration.

RESULTS

Motor Activity and Cytoarchitecture of the Cerebellar Cortex of Albino Rats

Table 1: Motor Activity

Group	Cyanide Dose (mg/kg)	Rotarod Latenccy (sec)	Open Field Distance (cm)
A	0	120.4 ± 5.2	1450 ± 110
B	100	110.2 ± 6.1	1320 ± 95
C	200	95.6 ± 7.3*	1085 ± 90*
D	300	78.4 ± 6.9*	920 ± 85*
E	400	62.5 ± 8.0**	740 ± 80**
F	500	48.3 ± 9.2**	580 ± 75**

*Significant at $p < 0.05$; **Significant at $p < 0.01$ compared to control.

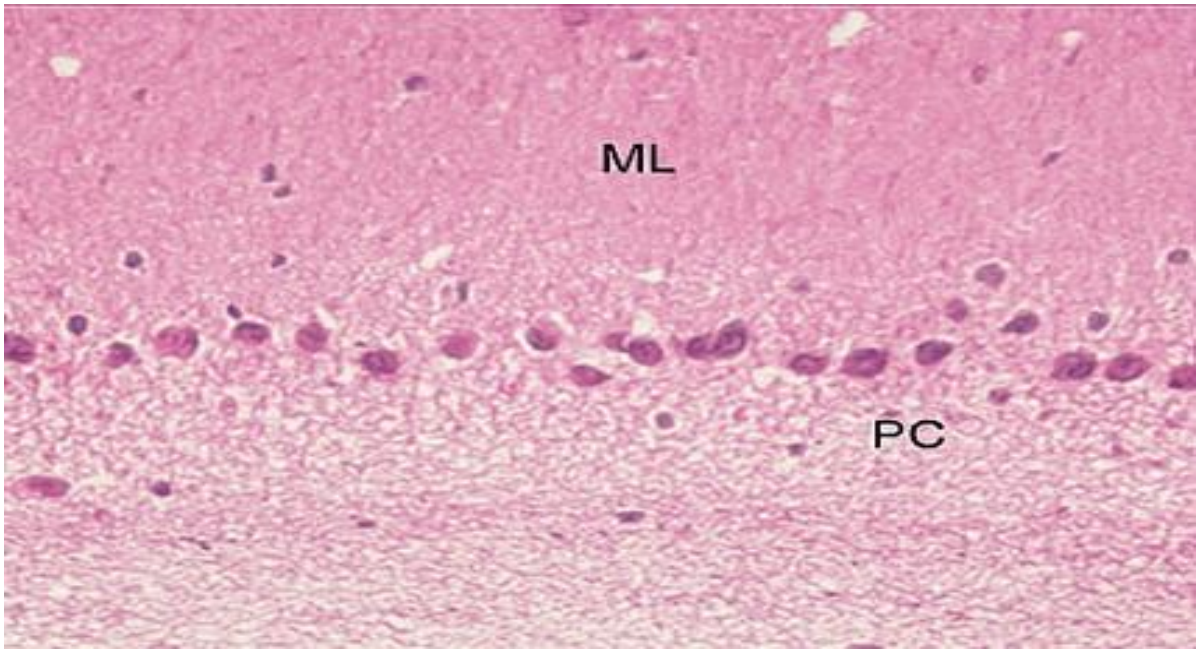

Figure 1: Normal cerebellar with infact Purkinje cells. The Control – 0 mg/kg) with Well-defined cerebellar layers: molecular layers (ML), Purkinje cell layer (PC), and granular layer (GL). The Purkinje cells are large, round, and neatly aligned with dark-stained nuclei with no signs of vacuolation or gliosis.

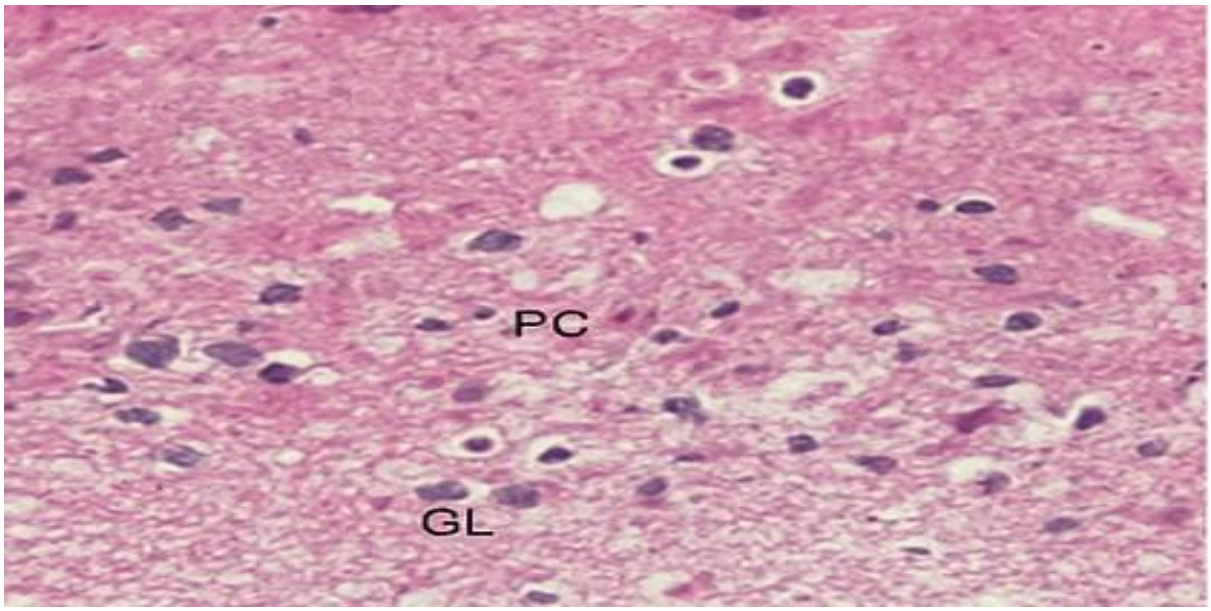

Figure 2: Mild vacuolation and slight Purkinje cell shrinking (100mg/kg cassava cyanide), Mild vacuolation in the ML seen. The Slight shrinkage of Purkinje cells but still present in a linear array. While the GL remains intact with subtle changes in staining intensity.

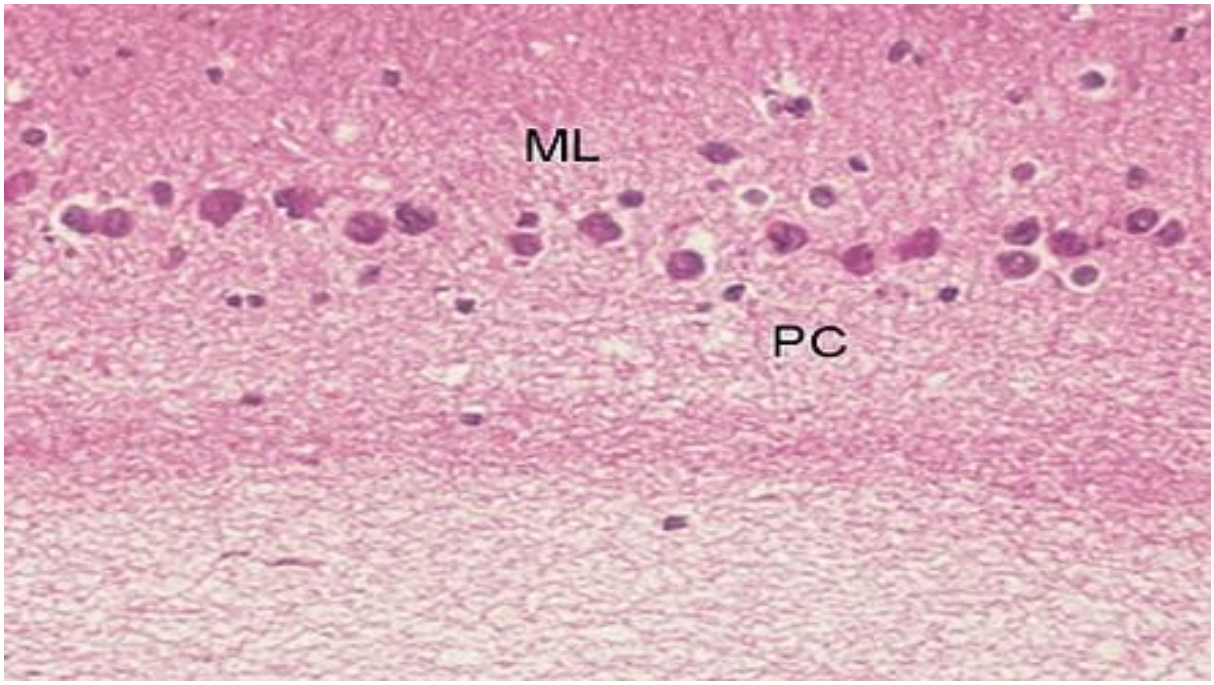

Figure 3: Moderate Purkinje cell loss and gliosis (200mg/kg cassava cyanide) A Noticeable reduction in Purkinje cells was observed and gliosis evident—small, dark-stained glial cells proliferate in ML and GL was also observed and with gaps in the Purkinje cell layer.

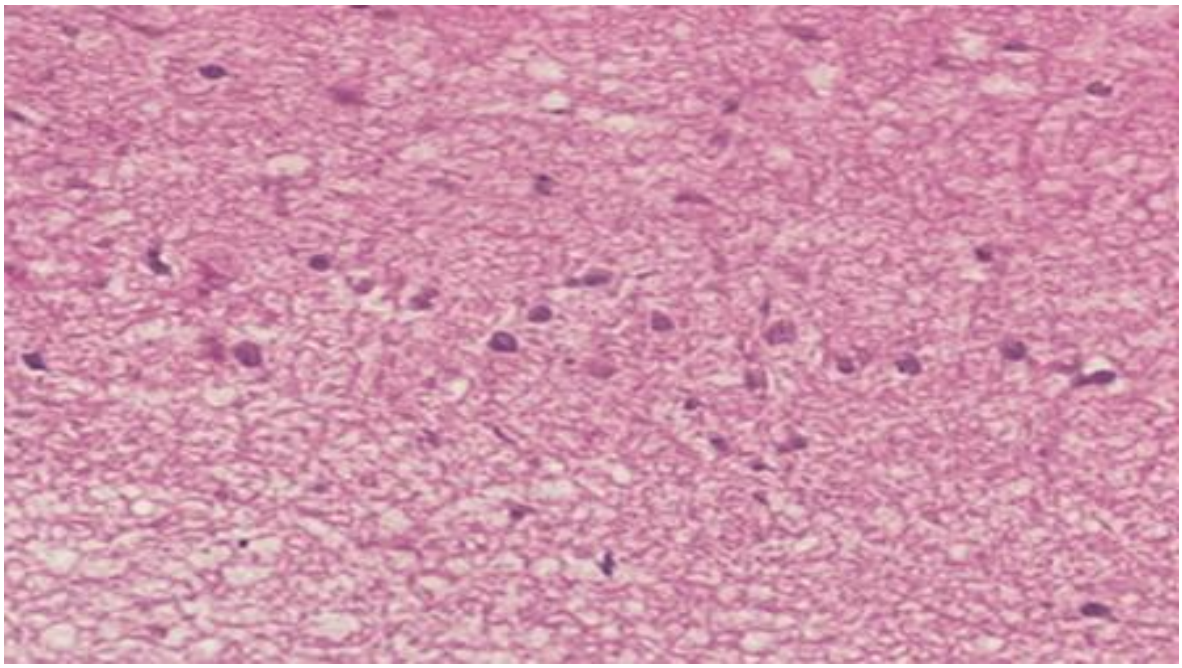

Figure 4: Disrupted laminar organization and increased vaguolation (300mg/kg cassava cyanide). This shows Laminar disorganization: ML and GL boundaries blurred with increased vacuolation throughout cortex. As well as purkinje cells scattered and irregular.

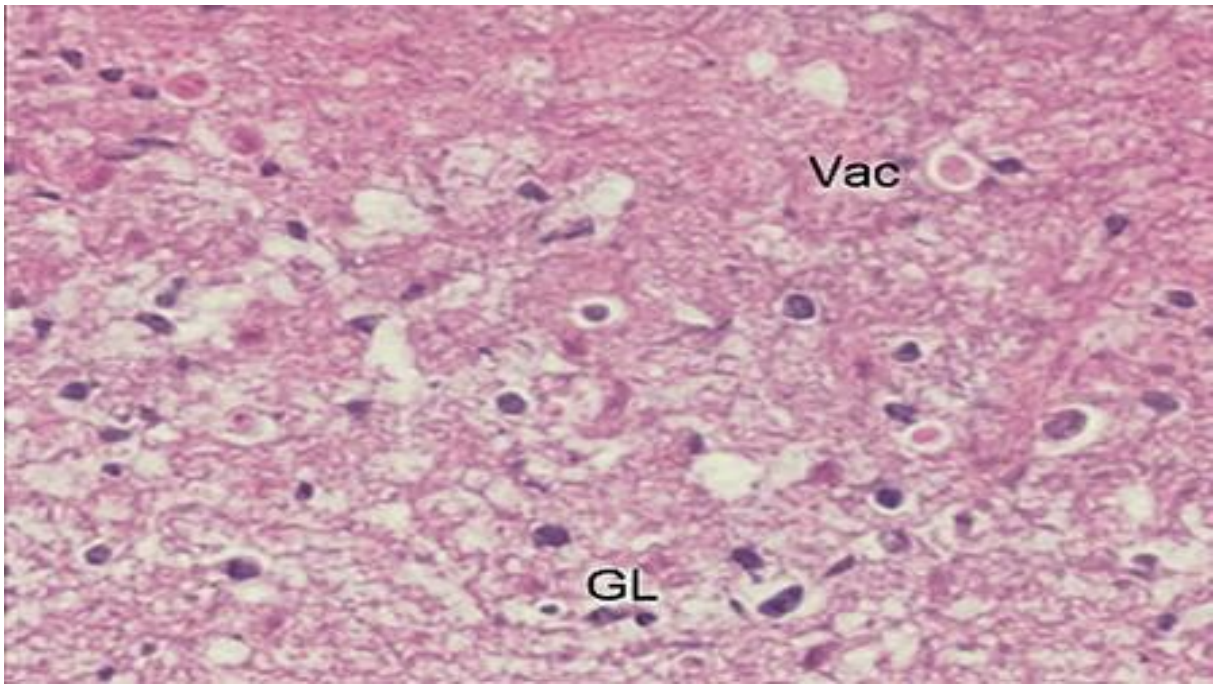

Figure 5: Severe Purkinje cell degeneration and cortical thinning (400mg/kg cassava cyanide). It shows a very severe degeneration of Purkinje cells—most are absent, with the

cortical thinning with indistinct ML and GL. Prominent gliosis and vacuolation was also observed

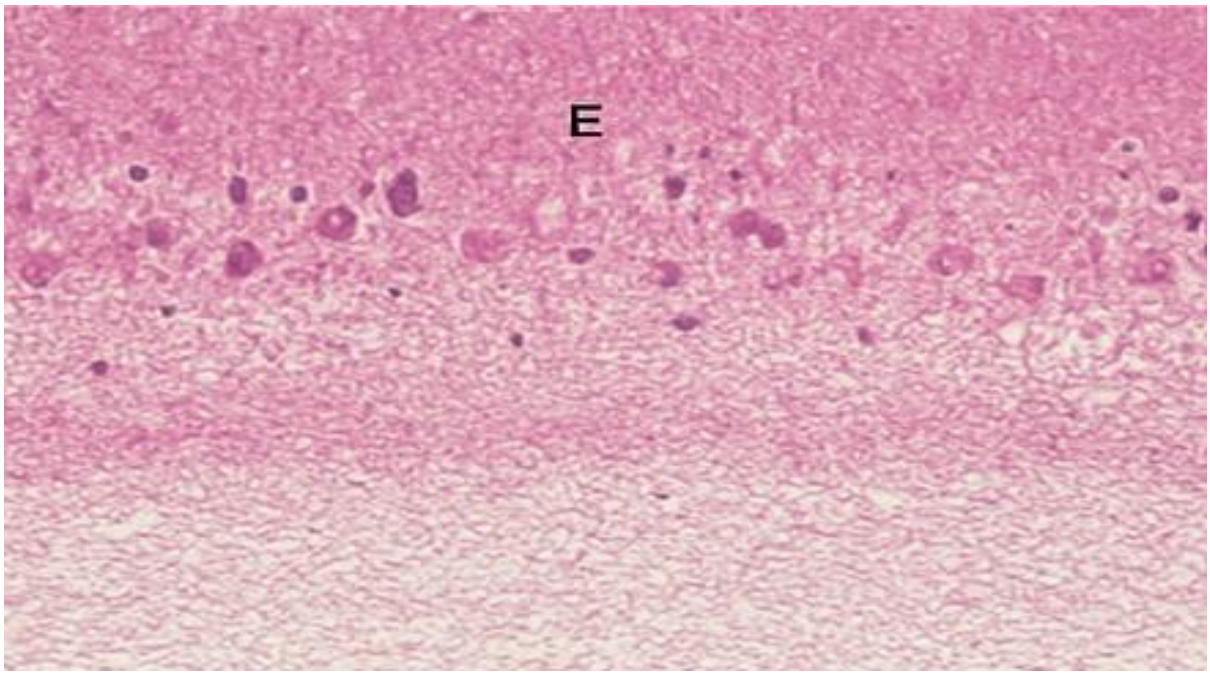

Figure 6: Extensive neuronal gliosis and complete disorganization of cerebellar layers (500mg/kg cassava cyanide). An extensive neuronal loss and complete disorganization of cerebellar layers was observed with ML and GL blend together; no identifiable Purkinje cells was seen. A dense gliosis and widespread vacuolation.

DISCUSSION

The present study demonstrates a clear dose-dependent neurotoxic effect of cassava-derived cyanide on motor activity and cerebellar cytoarchitecture in albino Wistar rats. Behavioral assessments revealed progressive motor deficits with increasing cyanide dosage, as evidenced by reduced rotarod latency and diminished open field locomotion. Histological analysis further confirmed structural deterioration of the cerebellar cortex, particularly affecting Purkinje cells, which are essential for motor coordination and balance.

These findings are consistent with previous research highlighting the vulnerability of the cerebellum to cyanide-induced oxidative stress and mitochondrial dysfunction. Cyanide inhibits cytochrome c oxidase in the mitochondrial electron transport chain, leading to ATP depletion and increased reactive oxygen species (ROS), which contribute to neuronal apoptosis and gliosis (Kimani et al., 2013). The observed gliosis and vacuolation

in higher-dose groups (400–500 mg/kg) align with this mechanism, indicating a compensatory glial response to neuronal injury.

The dose-dependent degeneration of Purkinje cells observed in this study mirrors findings by Ayuba (2015), who reported similar cerebellar damage in rats exposed to potassium cyanide. Ayuba's study noted Purkinje cell shrinkage, vacuolation, and laminar disorganization, particularly at higher cyanide concentrations, reinforcing the cerebellum's sensitivity to cyanogenic compounds.

Furthermore, the behavioral impairments observed in this study, such as reduced locomotor activity and poor balance are comparable to clinical manifestations of konzo and tropical ataxic neuropathy (TAN) in humans. Konzo, a non-progressive spastic paraparesis linked to cassava consumption, has been associated with upper motor neuron damage and cerebellar dysfunction (Enefa, Paul, & David, 2020). The motor deficits in rats exposed to 300–500 mg/kg cyanide resemble the motor impairments seen in konzo patients, suggesting that this animal model effectively simulates cassava-related neurotoxicity.

Manalo, et al., (2025) emphasized the role of protein carbamoylation in cyanide-induced neurodegeneration, noting that cyanate, a byproduct of cyanide metabolism can modify neuronal proteins and impair their function. This biochemical pathway may underline the structural disintegration observed in the cerebellar cortex at higher cyanide doses in the current study.

Rivadeneyra-Domínguez and Rodríguez-Landa (2020) also reported that chronic cassava consumption in rodents led to significant neurobehavioral changes and histopathological damage in the brain, particularly in regions involved in motor control. Their findings support the notion that cassava cyanide, even at sub-lethal doses, can disrupt neural integrity and behavior over time.

In contrast to some earlier studies that focused primarily on cortical or spinal effects, this study provides a focused analysis of cerebellar architecture, offering new insights into how cassava cyanide specifically affects cerebellar neurons and motor coordination. The use of graded doses (100–500 mg/kg) allowed for a nuanced understanding of the threshold and progression of neurotoxicity, which is critical for establishing safe dietary limits and informing cassava processing guidelines.

Overall, the results underscore the importance of proper cassava detoxification and adequate dietary protein intake to mitigate cyanide toxicity. Public health interventions in cassava-dependent regions should prioritize education on safe processing techniques and nutritional supplementation to prevent neurodegenerative outcomes.

CONCLUSION

This study provides compelling evidence that cassava-derived cyanide exerts dose-dependent neurotoxic effects on the motor activity and cerebellar cytoarchitecture of albino Wistar rats. Behavioral assessments revealed significant impairments in motor coordination and locomotion, particularly at higher doses (300–500 mg/kg), which were strongly correlated with progressive histopathological damage in the cerebellar cortex. The most severe effects included Purkinje cell degeneration, cortical thinning, gliosis, and complete disruption of cerebellar laminar organization. These findings align with previous research indicating that cyanide disrupts mitochondrial respiration and induces oxidative stress, leading to neuronal apoptosis and structural disintegration (Kimani et al., 2013; Ayuba, 2015). The cerebellum's vulnerability, especially its metabolically active Purkinje cells make it a critical target for cyanide toxicity. The observed motor deficits mirror clinical features of cassava-related neurodegenerative disorders such as konzo and tropical ataxic neuropathy (Enefa, Paul, & David, 2020), reinforcing the translational relevance of this animal model.

Importantly, the study highlights the dangers of consuming inadequately processed bitter cassava, especially in protein-deficient populations where cyanide detoxification is compromised. The graded dosing approach used in this experiment offers a nuanced understanding of the threshold and progression of cyanide-induced neurotoxicity, which can inform public health policies and dietary recommendations. In conclusion, cassava cyanide poses a significant neurotoxic threat when consumed in high concentrations or without proper detoxification. Public health interventions should prioritize education on safe cassava processing techniques and promote protein-rich diets to mitigate the risk of cyanide-induced neurological damage. Further research is warranted to explore protective strategies, including antioxidant supplementation and molecular biomarkers for early detection of cyanide neurotoxicity.

Conflict of Interest

The authors affirm that there are no conflicts of interest associated with this publication.

Authors' Declaration

The authors confirm that the research presented in this article is entirely original. They accept full responsibility for any claims or issues arising from the content herein.

REFERENCES

Abdulbasit, A. (2014). *Motor and memory function in rat models of cyanide toxicity*. Retrieved December 13, 2025, from https://www.academia.edu/115813539

Adamolekun, B. (2011). Neurological disorders associated with cassava diet: A review. *Metabolic Brain Disease, 26*(1), 79–85. https://doi.org/10.1007/s11011-011-9237-y

Ayuba, A. (2015). Cerebellar and cortical neurodegeneration in cyanide induced toxicity. *Global Journal of Animal and Environmental Biology, 3*(1), 32–37. https://globalscienceresearchjournals.org/journals/global-journal-of-animal-and-environmental-biology/pdf/2015/jan/Ayuba.pdf

Garg, R. K. (2024, December 13). Lathyrism, konzo, and tropical ataxic neuropathy. In *MedLink Neurology*. Retrieved December 13, 2025, from https://www.medlink.com/articles/lathyrism-konzo-and-tropical-ataxic-neuropathy

Jørgensen, K., Bak, S., Busk, P. K., Sørensen, C., Olsen, C. E., Puonti-Kaerlas, J., & Møller, B. L. (2011). Biosynthesis of the cyanogenic glucosides linamarin and lotaustralin in cassava: Isolation, biochemical characterization, and expression pattern of CYP71E7, the oxime-metabolizing cytochrome P450 enzyme. *Plant Physiology, 155*(1), 282–292. https://doi.org/10.1104/pp.110.164053

Kimani, S. T. (2014). *Neurotoxicity of cassava cyanogens in rodents and non-human primates* (Doctoral dissertation, University of Nairobi). University of Nairobi eRepository. https://erepository.uonbi.ac.ke/handle/11295/75633

Manalo, R. V., Ong, A. L., & Medina, P. M. (2025). Neurotoxic and neuromotor effects of cyanate, an oxidative byproduct of cyanide from linamarin in cassava: A systematic review. *The North African Journal of Food and Nutrition Research, 9*(19), 85–94. https://doi.org/10.51745/najfnr.9.19.85-94

Ndubuisi, N. D., & Chidiebere, A. C. U. (2018). Cyanide in cassava: A review. *International Journal of Genomics and Data Mining, 2*(1), Article 118. https://doi.org/10.29011/2577-0616.000118

Nzwalo, H., & Cliff, J. (2011). Konzo: From poverty, cassava, and cyanogen intake to toxico-nutritional neurological disease. *PLOS Neglected Tropical Diseases, 5*(6), e1051. https://doi.org/10.1371/journal.pntd.0001051

Rivadeneyra-Domínguez, E., & Rodríguez-Landa, J. F. (2020). Preclinical and clinical research on the toxic and neurological effects of cassava (Manihot esculenta Crantz) consumption. *Metabolic Brain Disease, 35*, 65–74. https://doi.org/10.1007/s11011-019-00522-0